

TECHNIQUE

The Extended Flexor Carpi Radialis Approach: A New Perspective for the Distal Radius Fracture

JORGE L. ORBAY, M.D.
ALEJANDRO BADIA, M.D.
IGOR R. INDRIAGO, M.D.
*Miami Hand Center,
Miami, FL, U.S.A.*

ANTHONY INFANTE, D.O.
*Florida Orthopaedic Institute,
Tampa, FL, U.S.A.*

ROGER K. KHOURI, M.D.
EDUARDO GONZALEZ, M.D.
*Miami Hand Center,
Miami, FL, U.S.A.*

DIEGO L. FERNANDEZ, M.D.
*Lindenhof Hospital,
Berne, Switzerland*

■ HISTORICAL PERSPECTIVE

Volar fixation of dorsally unstable distal radius fractures is a new method of treatment that provides the benefits of stable internal fixation without the complications of the dorsal approach. A new, fixed-angle fixation device, the distal volar radius (DVR) plate, (Fig. 1) has been introduced for this purpose. Experience gained by applying this technique to clinically complex cases led us to the realization that more exposure, especially in a dorsal direction, was necessary than that provided by the traditional volar approaches. The need to reduce fractures with significant articular displacement (Fig. 2) and the need to release dorsal callus in inveterate fractures or nascent malunions led us to use an extended form of the flexor carpi radialis (FCR) approach.

Volar displaced distal radius fractures are commonly managed with volar buttress plates through the FCR approach.¹ This approach goes deep to the forearm fascia through the FCR tendon sheath and is continuous with

the distal part of the Henry approach. The traditional FCR approach provides access to the volar aspect of the distal radius, the volar wrist capsule, and the scaphoid. In comparison with dorsal approaches, which present a high incidence of extensor tendon problems,²⁻⁶ the FCR approach is relatively free of complications.

We extend the FCR approach by releasing the radial septum, by mobilizing the proximal radial fragment, and by using the fracture plane for exposure or what is known as intrafocal technique. Therefore, understanding the anatomy of the radial septum is important. On its proximal aspect, it is a simple fascial wall separating the flexor and extensor compartments of the forearm. At the level of the radial metaphysis, the radial septum is a complex fascial structure that includes the first extensor compartment and the insertion of the brachioradialis. More distally, the radial septum forms the radial insertion of the carpal ligament and ends as the FCR tendon sheath approaches the tuberosity of the scaphoid. The proximal radial fragment has a dependable endosteal blood supply that permits its subperiosteal release and subsequent mobilization. Pronating this fragment out of the way provides wide exposure of the fracture surfaces. This allows the volar reduction and fixation of even the most complex dorsally displaced distal radius fractures.

Address correspondence and reprint requests to Dr. Jorge L. Orbay, Miami Hand Center, 8905 SW 87 Ave., Suite 100, Miami, Florida 33176; e-mail: MIAHANDS@ix.netcom.com




FIG. 1. The distal volar radius (DVR) plate (Hand Innovations, Miami, FL) is a fixed-angle device designed specifically for the general volar fixation of distal radius fractures. The purpose of this surgical strategy is to avoid the tendon complications common with the dorsal approach. The extended flexor carpi radialis approach allows the management of the most complex distal radius fractures.

■ INDICATIONS/CONTRAINDICATIONS

This technique is indicated for distal radius fractures in which simpler forms of management would produce unacceptable results. Unstable fractures in young and active patients, which need optimal restoration of the bony anatomy; in polytraumatized patients with complex rehabilitation issues, which might include lower-extremity injuries; or in elderly patients who need a quick return to functional independence are all good indications for this technique. We define fractures as unstable if, after an attempt at close reduction, they persist with radiographic evidence of more than 15 degrees of angulation in any

plane, a greater than 2-mm articular step-off, or greater than 2 mm of shortening. Also, fractures with severe comminution, severe articular displacement, or poor bone quality can be considered unstable. Patients with inveterate fractures or nascent malunions are also good candidates for this technique.

■ TECHNIQUE

The skin incision is made directly over the course of the FCR tendon and is 8–10 cm long. It should zigzag across the wrist flexion creases (Fig. 3). The tendon tunnels along the forearm fascia, dividing it into a superficial deep layer. This forms a strong fascial structure that allows for safe retraction. The superficial layer of the sheath is incised longitudinally, and the FCR tendon is retracted medially, protecting the median nerve. The floor of the sheath is then incised to gain deep access (Fig. 4). Proximally, the tendon sheath should be released generously to facilitate exposure. Distally, both layers should be divided up to the tuberosity of the scaphoid. This structure underlies the crossing of the superficial radial artery and forms the distal limit of the radial septum.

The dissection is taken down to the surface of the distal radius by developing the space between the flexor pollicis longus and the radial septum. Numerous muscular perforators are found here and need to be cauterized. The radial origins of the most distal fibers of the flexor pollicis longus muscle are released for greater exposure. The space of Parona, the virtual space between the flexor tendons and the volar surface of the pronator quadratus, is now developed. This is accomplished by blunt digital

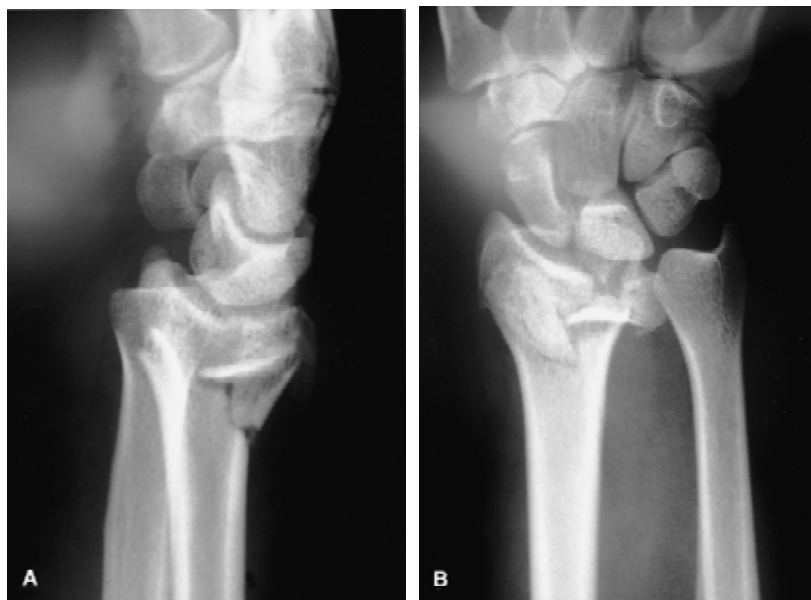

FIG. 2. (A and B) A fall from a roof produced this dorsally unstable distal radial fracture with a displaced, dorsal, die-punch fragment.

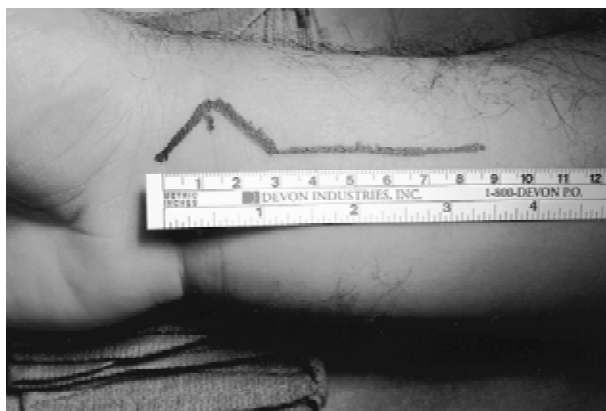


FIG. 3. The skin incision is made directly over the course of the flexor carpi radialis tendon, zigzags across the flexion creases, and is 8–10 cm long.

dissection and by sharp division of the proximal reflexion of the carpal bursa. This exposes the distal radius, the pronator quadratus muscle, and the anterior wrist capsule (Fig. 5). The pronator quadratus is mobilized by releasing its distal and lateral borders with an L-shaped incision. It is then lifted from its bed by subperiosteal dissection, exposing the fracture site. The distal border of the pronator quadratus forms a transverse line on the surface of the radius. This line marks the proximal reflection of the carpal bursa and signals the distal limit for safe hardware placement (Fig. 6). With dorsally displaced injuries, the pronator quadratus muscle fibers are frequently found torn and interposed in the fracture site.⁷

So far in this report we have described the classic FCR approach. Many fresh fractures (less than 10 days old) can be managed easily with only this exposure, because longitudinal traction in the presence of intact dor-

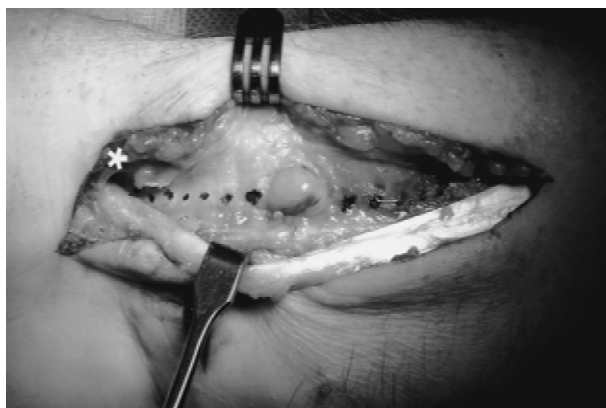

FIG. 4. The dissection goes deep to the forearm fascia through the sheath of the FCR tendon and is continued down between the flexor pollicis longus and the radial septum. Note distally the superficial branch of the radial artery (*).

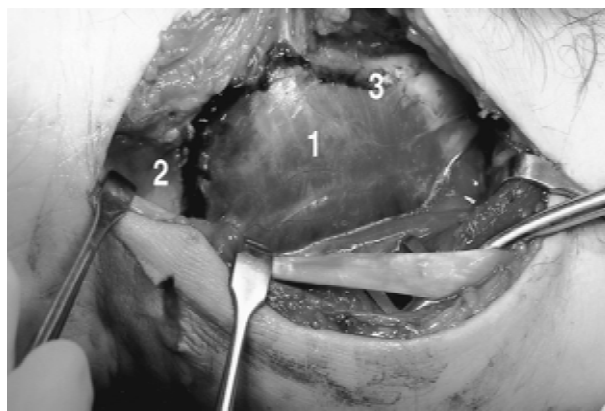


FIG. 5. The space of Parona is developed by exposing the distal radius, (1) the pronator quadratus muscle, (2) and the anterior wrist capsule (3). The distal and lateral borders of the pronator quadratus muscle are marked for release.

sal soft tissues will produce an adequate reduction. This is the well-known phenomenon of ligamentotaxis. On the other hand, fractures that present severe intraarticular displacement or organizing fracture hematomas will not reduce adequately with this simple technique.

The need for the extended FCR approach arises in cases. The fracture plane is used for exposure; this is also known as “intrafocal technique.” This is analogous to the approach for a tibial plateau fracture. Here the metaphyseal fragment is “opened like a book,” allowing the joint surface to be viewed from within the fracture. The FCR approach is extended in three steps: the release of the radial septum, the subperiosteal release of the proximal radial fragment, and its mobilization into pronation. This last maneuver provides direct access to the fracture

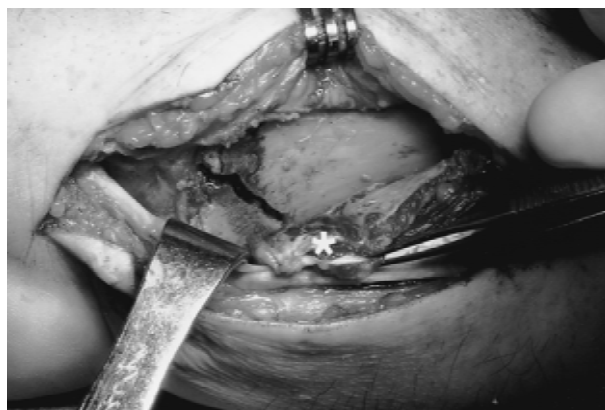

FIG. 6. The pronator quadratus is elevated exposing the fracture. This completes the classic part of the flexor carpi radialis approach. Note the transverse line formed by the distal edge of the pronator quadratus muscle (*). The line indicates the distal limit for the safe application of hardware.

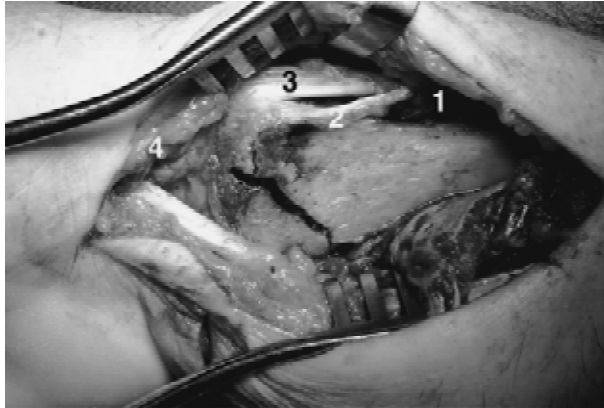


FIG. 7. Extension of the flexor carpi radialis approach requires the release of the radial septum. Proximally, this structure is a simple fascial wall, separating the flexor and extensor compartments (1). More distally, it becomes a complex fascial structure that includes the insertion of the brachioradialis (2) and the first extensor compartment (3). Finally, it becomes the radial insertion of the carpal ligament (4).

surfaces, permitting reduction of articular displacement, bone grafting, and the removal of fracture callus.

Proximally, the radial septum is a simple fascial wall separating the flexor from the extensor compartments and is released easily from its radial insertion. Just proximal to the styloid process, the septum becomes a complex fascial structure formed in part by the first extensor compartment and by the insertion of the brachioradialis. The radial artery is vulnerable in this area. To release the radial septum here, the first extensor compartment is opened and its tendons retracted. The insertion of the brachioradialis is found on the floor of this compartment. It limits dorsal exposure and produces a deforming force. Therefore its release greatly facilitates the exposure and

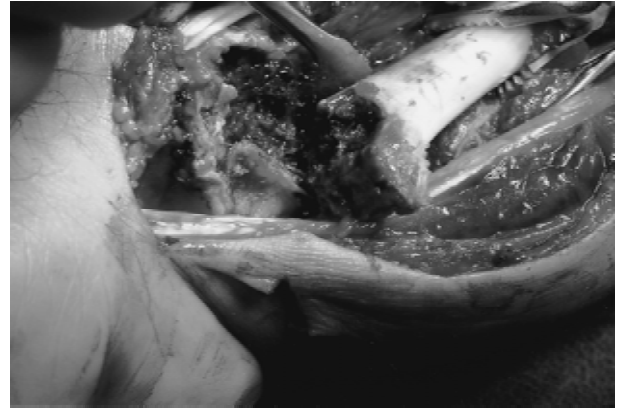

FIG. 9. Pronating the proximal fragment out of the way with the help of a bone clamp provides comfortable access to the fracture surfaces.

reduction of the fracture. Distal to the styloid process, the radial septum becomes less distinct and also serves as the insertion of the carpal ligament. It is released by dissecting toward the tuberosity of the scaphoid (Fig. 7).

The periosteum is released around the proximal radial fragment to permit its mobilization. This is done safely, as this fragment is provided with a dependable endosteal blood supply. The surgeon should preserve the soft tissue attachments to the dorsal aspect of the distal fragment and to comminuted dorsal fragments (Fig. 8).

The proximal radial fragment is mobilized into pronation to complete the exposure. The use of a bone clamp as a handle facilitates this action, and the fracture can be disimpacted if necessary (Fig. 9). Once the proximal radial fragment is out of the way, the surgeon has direct access to the fracture surfaces. It is possible to manipulate articular fragments directly. These can be molded against the carpus, which serves as a template, to obtain reduction (Fig. 10). Access to the dorsal aspect of the fracture site is also obtained. This allows the debride-

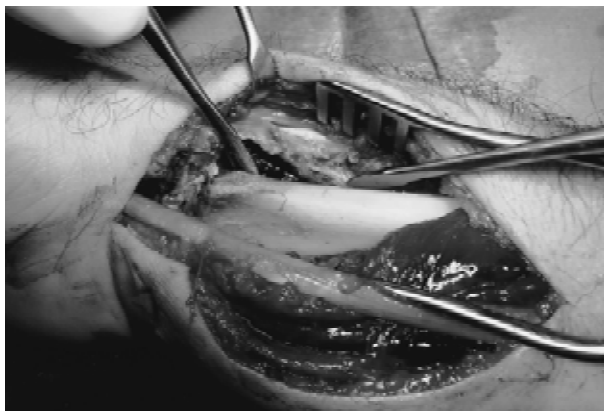

FIG. 8. The dependable endosteal blood supply of the proximal radial fragment permits its generous release and mobilization.

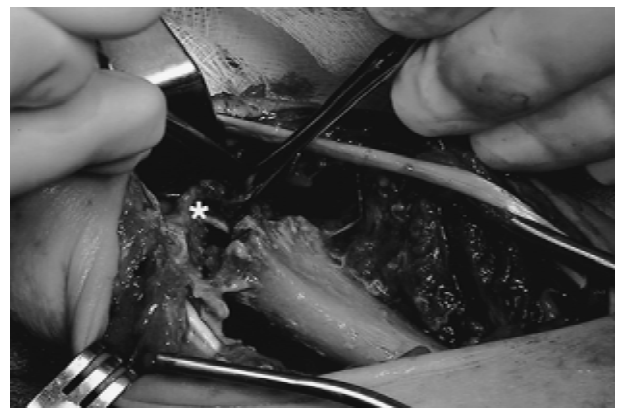


FIG. 10. Articular fragments (*) can be manipulated directly. The carpus can serve as template for reduction.

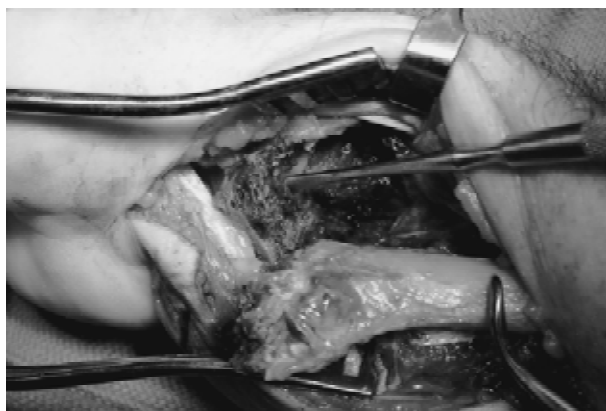


FIG. 11. The approach allows access to the dorsal aspect of the fracture, the debridement of organized hematoma or fracture callus, and the application of bone graft.

ment of organized hematoma or callus to accomplish reduction in the case of an inveterate fracture. In the case of a true nascent malunion, the ossified callus and hypertrophic dorsal periosteum can be removed (Fig. 11). Bone graft can also be applied, if necessary, through this approach. The proximal radial fragment is finally supinated back into position “closing the book” (Fig. 12).

Once adequate reduction has been obtained, fixation is applied on the volar surface of the radius (Fig. 13). The DVR plate has fixed angle pegs, directed to key regions of the distal radius, to assure fixation of the common fracture fragments. The most radial peg is directed into the styloid process, and the most ulnar peg is directed into the dorsal dye punch fragment. The volar dye punch fragment is supported by the plate’s volar lip, and, if necessary, additional fixation can be applied. This volar fragment is, in our experience, the most difficult to fix. Comminuted fractures therefore can be stabilized effectively.

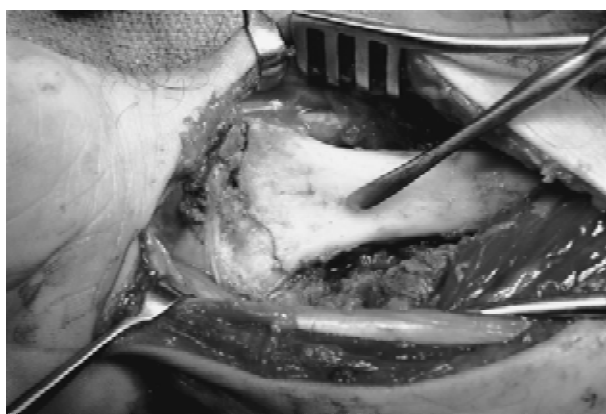


FIG. 12. After proper articular reduction is obtained and bone graft applied, the proximal fragment is reduced back in place. This produces a stable situation allowing the application of the plate.

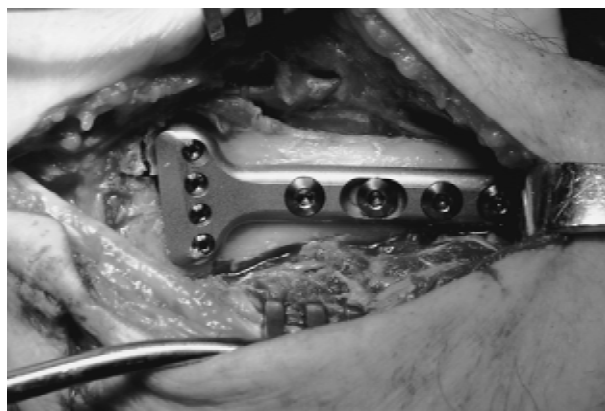

FIG. 13. The distal volar radius (DVR) plate is applied proximal to the transverse line formed by the distal border of the pronator quadratus.

Proper reduction of the fracture and positioning of the hardware is confirmed with fluoroscopy (Fig. 14). It is necessary to obtain the correct views. For the lateral view, the forearm must be elevated 20 degrees from the horizontal and the articular surface visualized tangentially to assure proper placement of the pegs in the subchondral bone. The brachioradialis and pronator quadratus are finally sutured back in place to retain the bone graft, to cover the implant, and to separate it from the flexor tendons (Fig. 15)(Fig. 16 and 17). Internal fixation of an associated scaphoid fracture can be achieved by incising the volar capsule. Carpal tunnel release should be performed through a separate incision, because it has

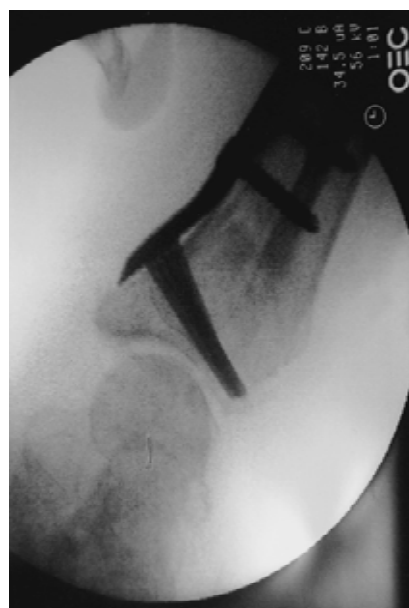

FIG. 14. Proper placement of the pegs in the subchondral bone is confirmed fluoroscopically.

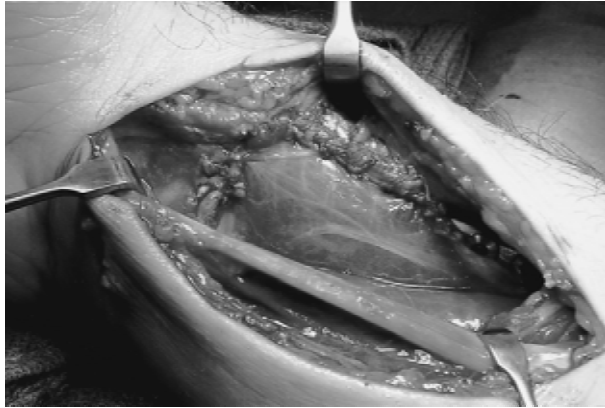


FIG. 15. The brachioradialis and the pronator quadratus are returned to their original positions, covering the plate and protecting the flexor tendons.

been our experience that complete release of the radial insertions of the carpal ligament is associated with flexor pollicis longus dysfunction, and the palmar cutaneous nerve is at risk if the incision is extended ulnarly and distally into a standard carpal tunnel release. Continuation of the dissection on the plane of the interosseous membrane toward the ulnar side can expose the distal ulna. In the case of a distal ulna fracture that cannot be fixed in an elderly patient, the distal ulna can be excised from this approach; and it is also possible to perform an ulnar shortening osteotomy through this incision.

■ COMPLICATIONS

With vigilance and careful technique, most complications can be avoided. Flexor tendon problems have not

occurred with our technique. We have seen dorsal tendon irritation from an excessively long peg. This is managed with hardware removal. Full-blown RSD has also not occurred. Its milder forms presenting as slow progress in rehabilitation or pain and swelling out of proportion to the injury are occasionally seen. This problem responds well to early treatment, which in our center includes intensive physiotherapy, calcitonin, and sympathetic blocks. We expect full digital motion by the first week, and its absence is managed aggressively. All our patients regained full digital motion by the end of treatment. There were no cases of deep infections, shortening, or loss of reduction when the DVR plate was used. No breakage of the implant occurred.

Concomitant ligamentous injuries, both intercarpal and distal radioulnar, frequently occur. They should be looked for and managed early. Persistent pain long after a distal radius fracture can be caused by one of these easily missed injuries. Carpal tunnel syndrome is not uncommon after distal radius fractures. We search for paresthesias before surgery and very frequently release the carpal tunnel in high-risk patients.

■ REHABILITATION

Finger motion and forearm rotation is commenced immediately after surgery. After removal of the postoperative dressing, a short splint is frequently used for symptomatic relief. Extra-articular fractures generally have less soft-tissue swelling and return to function faster. Intraarticular fractures often have more soft-tissue reaction and benefit from a more prolonged period of wrist splinting. The use of the hand for light activities of daily

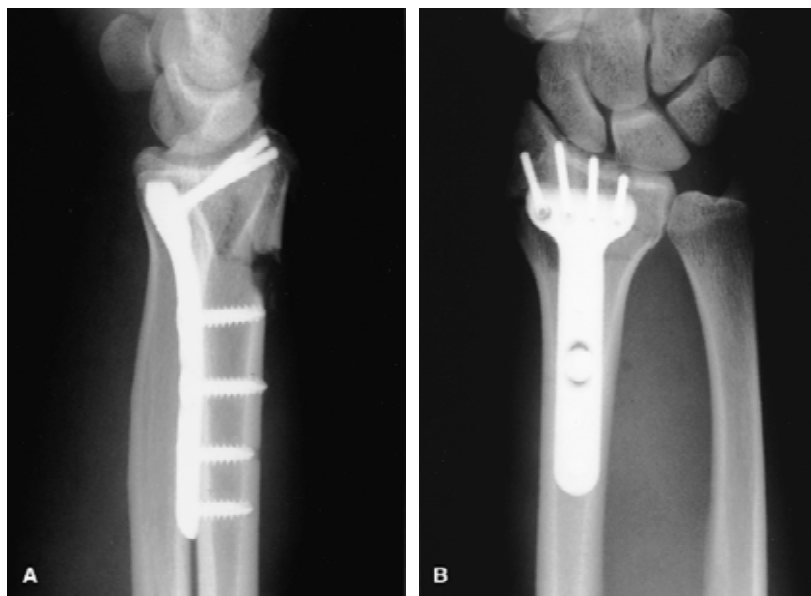


FIG. 16. (A and B) The result is anatomic restoration of the articular surface and correct radial length.

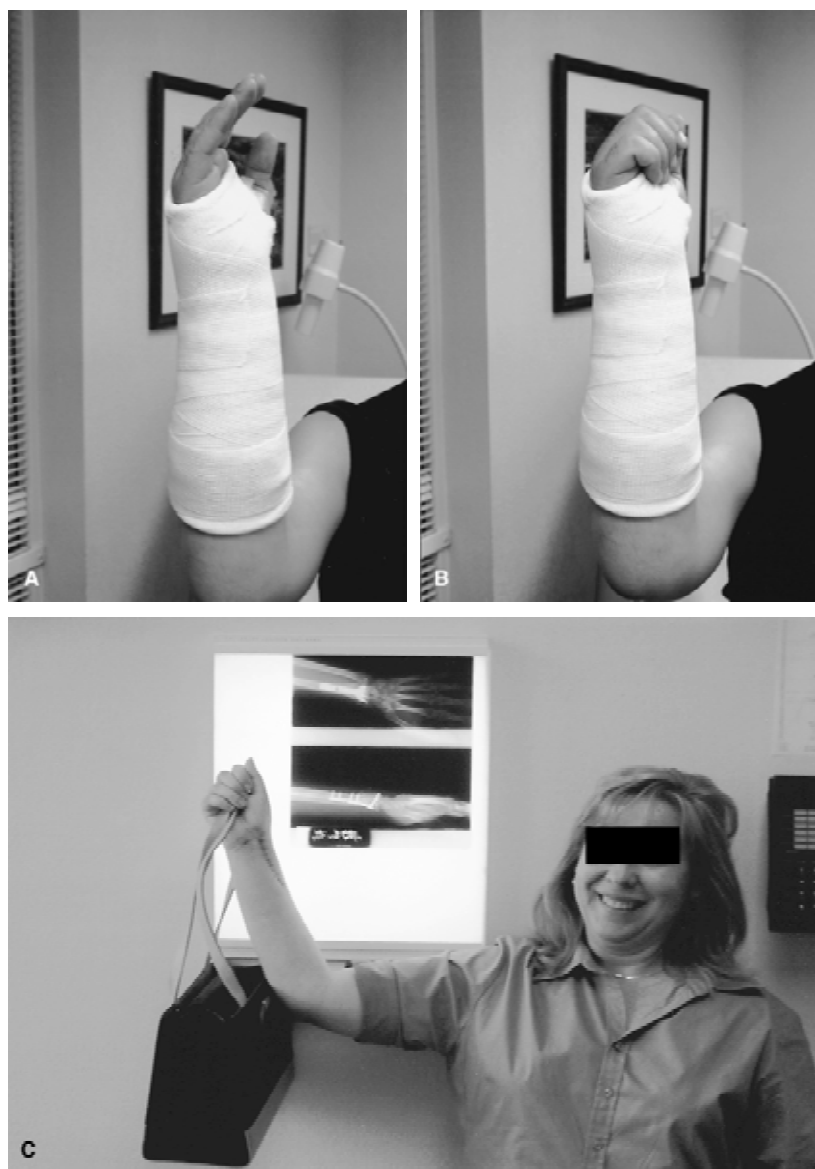

FIG. 17. (A, B, and C) Rehabilitation consists of immediate postoperative finger and forearm motion, the early functional use of the hand, and the short-term use of wrist support to manage edema and facilitate early function.

living is encouraged at the first postoperative visit, and patients are then given reasonable weight-lifting restrictions. The weight limit is increased progressively, and no restrictions are applied after radiographic union is achieved. This usually occurs between the fourth and tenth weeks. Most patients are able to touch their palms with their fingertips at the first postoperative visit. Failure to do so results in a referral to formal physiotherapy.

■ DISCUSSION

Until recently, buttress plates were the only form of stable internal fixation available for distal radius fractures. The principle that volarly displaced fractures are approached from the volar side and dorsally displaced

fractures from the dorsal side originates from the need to apply the buttress plates on the unstable surface.

Stable internal fixation traditionally has been reserved for the volarly displaced fractures. Most surgeons have avoided the use of dorsal plates as they have been frequently associated with extensor tendon complications.⁸ Despite different designs of dorsal implants, their use commonly requires reoperation for removal. Tendon problems seem more inherent to the dorsal approach rather than to the specific implant characteristics. Attritional tendonitis occurs on the dorsal aspect of the distal radius, because there is little space available for the application of implants. There is more space on the volar aspect. Here the flexor tendons are well separated from the bone surface by the pronator quadratus muscle and

protected by the concave shape of the distal radius. These anatomic characteristics allow the safe application of volar plates. Volar fixation of these injuries also has other advantages. The volar approach preserves the dorsal soft tissues, allowing for ligamentotaxis and the maintenance of fragment vascularity. Rehabilitation seems to be hastened by the volar approach, and the volar scar is better accepted than the dorsal.

The DVR plate offers stable internal fixation to dorsally displaced distal radius fractures through a volar approach. It accomplishes this by using the fixed-angle principle⁹ to prevent toggling of the distal fragment and by a robust design that enables it to carry the high loads generated by this loading configuration. Expanding the indications for volar plate fixation to dorsal fractures reveals that the standard volar approaches do not always offer sufficient exposure. This is particularly true in the management of fractures with severe articular displacement and those with advanced callus formation. We have used an extended form of the FCR approach for the management of these fractures. Releasing the radial septum and mobilizing the proximal radial fragment to provide intrafocal exposure extends this approach. This maneuver provides the exposure necessary for the surgical management of complex clinical situations. The standard FCR approach is well known in the surgical community, and the extended form is easily mastered.

The inclusion of the extended FCR approach in the surgeon's armamentarium provides him with the ability to safely manage distal radius fractures with stable internal fixation, regardless of their direction of instability. This enables him to simplify the treatment of the polytraumatized patient, obtain better anatomic results

for high-energy injuries, and expedite a return to independent function for the elderly patient.

■ REFERENCES

1. Jupiter JB, Fernandez DL, Toh CL, et al. Operative treatment of volar intra-articular fractures of the distal end of the radius. *J Bone Joint Surg [Am]* 1996;78:1817–28.
2. Ring D, Jupiter JB, Brennwald J, et al. Prospective multicenter trial of a plate for dorsal fixation of distal radius fractures. *J Hand Surg [Am]* 1997;22:777–84.
3. Carter PR, Frederick HA, Laseter GF. Open reduction and internal fixation of unstable distal radius fractures with a low-profile plate: A multicenter study of 73 fractures. *J Hand Surg [Am]* 1998;23:300–7.
4. Kambouroglou GK, Axelrod TS. Complications of the AO/ASIF titanium distal radius plate system (II plate) in internal fixation of the distal radius: A brief report. *J Hand Surg [Am]* 1998;23:737–41.
5. Hove LM, Nilsen PT, Furnes O, et al. Open reduction and internal fixation of displaced intraarticular fractures of the distal radius. *Acta Orthop Scand* 1997;68:59–63.
6. Axelrod TS, McMurtry RY. Open reduction and internal fixation of comminuted, intraarticular fractures of the distal radius. *J Hand Surg [Am]* 1990;15:1–10.
7. Fernandez DL. Should anatomic reduction be pursued in distal radial fractures? *J Hand Surg [Br]* 2000;25:1–6.
8. Fernandez DL, Jupiter JB. Compression fractures of the articular surface. In: *Fractures of the Distal Radius*. New York; Springer 1996;189–220.
9. Gesenway D, Putnam MD, Mente PL, et al. Design and biomechanics of a plate for the distal radius. *J Hand Surg [Am]* 1995;20:1021–27.