

Bilateral Arthroscopic Tendon Interposition Arthroplasty of the Thumb Carpometacarpal Joint in a Patient With Ehlers-Danlos Syndrome: A Case Report

Alejandro Badia, MD, Felix Riano, MD, Lyle C. Young, BS, Miami, FL

A common finding in progressive osteoarthritis of the carpometacarpal joint of the thumb is ligamentous laxity. In patients with Ehlers-Danlos syndrome, which is a disorder characterized by generalized ligamentous laxity, splinting and arthrodesis have been recommended because of the random results achieved by other reconstructive procedures. We report a patient with thumb carpometacarpal joint osteoarthritis secondary to Ehlers-Danlos syndrome who was treated with bilateral arthroscopic tendon interposition arthroplasty. (*J Hand Surg* 2005;30A: 673–676. Copyright © 2005 by the American Society for Surgery of the Hand.)

Key words: Arthroscopy, tendon interposition, ligament laxity, carpometacarpal joint.

Ligamentous laxity has been identified as one of the anatomic findings frequently seen in progressive osteoarthritis of the thumb carpometacarpal (CMC) joint.^{1–3} Ehlers-Danlos syndrome, an inherited disorder characterized by abnormal collagen synthesis with skin extensibility and joint laxity, often compromises the hand and wrist.^{4–6} Involvement of the trapeziometacarpal joint as a result of this problem is not uncommon.⁶ Early splinting and arthrodesis have been recommended over other reconstructive procedures because of the unpredictable outcomes related to the generalized ligamentous laxity.^{4–6}

Previous reports on thumb CMC joint arthroscopy were a description of this technique as an evaluation tool and 1 article reported the results obtained with arthroscopic tendon interposition arthroplasty in patients without generalized joint laxity.^{7–9} We report arthroscopic interposition arthroplasty coupled with thermal capsular shrinkage in the setting of Ehlers-Danlos syndrome. Herein we describe bilateral arthroscopic tendon interposition arthroplasty of the thumb CMC joints by using a slip of the abductor pollicis longus tendon as a spacer in a patient with Ehlers-Danlos syndrome.

Case Report

A 56-year-old right-handed salesman with a history of Ehlers-Danlos syndrome presented with more than 1 year of steadily increasing pain at both thumb bases. The pain was worse in the right hand. On examination the patient showed visibly prominent basal joints, particularly on the right side with tenderness over the volar aspect. He demonstrated extreme skin and ligamentous laxity and was able to passively extend the metacarpophalangeal joints past

From the Miami Hand Center, Miami, FL.

Received for publication September 24, 2003; accepted in revised form January 2, 2005.

No benefits in any form have been received or will be received from a commercial party related directly or indirectly to the subject of this article.

Corresponding author: Alejandro Badia, MD, Hand, Upper Extremity and Microsurgery, Miami Hand Center, 8905 SW 87th Ave, Suite 100, Miami, FL 33176; e-mail: alexmd@ix.netcom.com.

Copyright © 2005 by the American Society for Surgery of the Hand 0363-5023/05/30A04-0004\$30.00/0

doi:10.1016/j.jhsa.2005.01.003

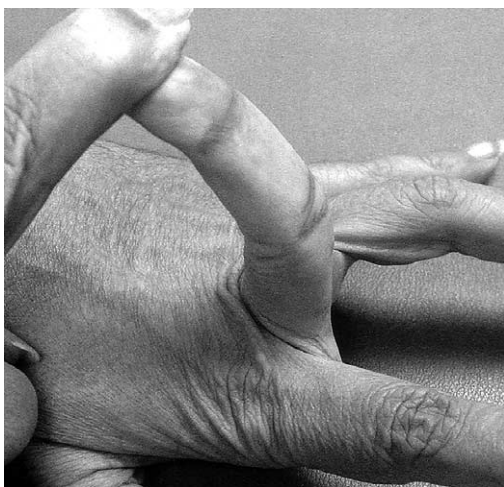

Figure 1. Ligamentous laxity shown in a patient with Ehlers-Danlos syndrome.

90°, passively oppose the thumb to the volar aspect of the forearm, hyperextend the elbow beyond 10°, hyperextend the knee beyond 10°, and forward flex the trunk until his palms could rest easily on the floor (Fig. 1). The grind test was positive on both joints. Pinch strength testing showed a right-sided deficit with a value of 7.3 kgf compared with 9.1 kgf on the left, nondominant side. Radiographs showed evidence that the bilateral basal joint subluxation was more pronounced on the right hand and narrowing of the joint space and some early marginal osteophytes (Fig. 2). Subchondral sclerosis also was evident, with no cyst being present.

Based on these findings the patient appeared to have bilateral, late stage III basal joint arthritis (according to Eaton's classification)^{5,10} secondary to Ehlers-Danlos syndrome. Arthroscopy of the right CMC joint was performed under wrist block regional anesthesia with tourniquet control. A single Chinese finger trap was used on the thumb with 2.3 kgf of longitudinal traction. The CMC joint then was detected by palpation. The incision for the 1-R (radial) portal was placed just volar to the abductor pollicis longus tendon. The incision for the 1-U (ulnar) portal tendon was performed just ulnar to the extensor pollicis brevis tendon. Joint distension was achieved by injecting 1 mL of normal saline and we used a short-barrel 1.9-mm 30°-inclination arthroscope. Joint evaluation revealed extensive synovitis and advanced osteoarthritis with extensive cartilage loss (Fig. 3). Therefore the decision was made to proceed with arthroscopic tendon interposition arthroplasty by using a slip of the abductor pollicis longus tendon because of the bilateral absence of the palmaris lon-

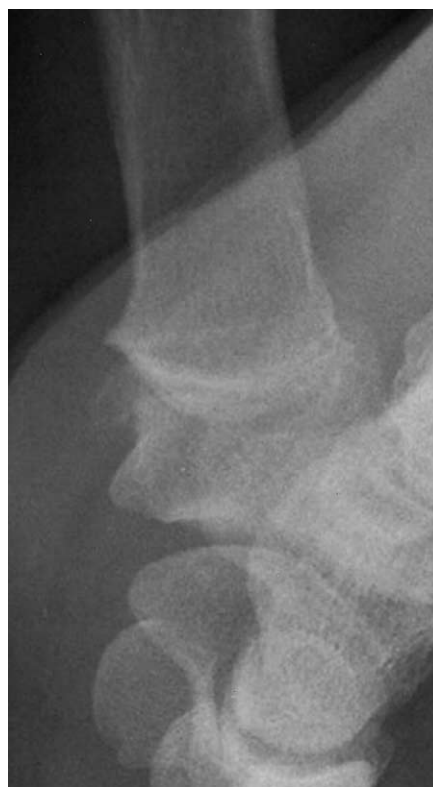

Figure 2. Preoperative radiographic study showing marginal osteophyte and bone-to-bone contact in stage III osteoarthritis.

gus. The ligamentous laxity and the capsular attenuation were treated with thermal capsulorrhaphy by using a radiofrequency shrinkage probe. We were careful to avoid thermal necrosis and hence a striping technique was used to tighten the capsule. A bur was placed through the radial portal to shave down the subchondral bone of the trapezium, increasing the

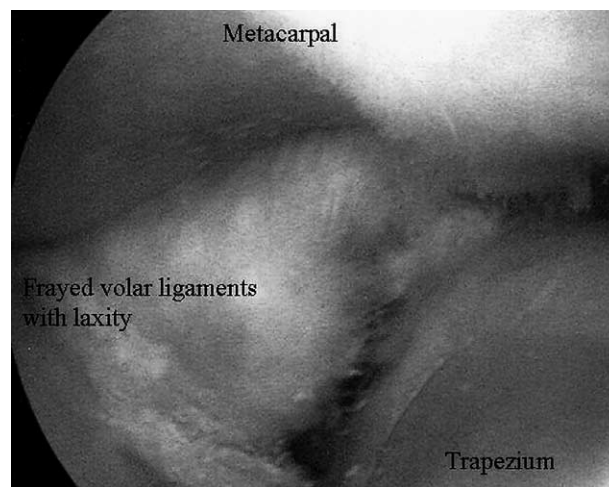


Figure 3. Arthroscopic findings seen in stage III osteoarthritis with capsular laxity indicative of Ehlers-Danlos syndrome.

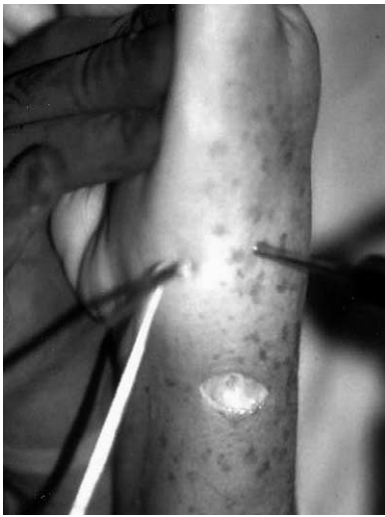

Figure 4. Basal joint arthroscopic procedure in the patient showing insertion of the interposition graft using a slip of the abductor pollicis longus.

joint space to perform the interposition arthroplasty and making the surface bleed to enhance the formation of adhesions to the tendon graft. Once this was completed we made a transverse incision over the dorsoradial aspect of the CMC joint, the radial sensory nerve was identified and protected, and we proceeded to open the first extensor compartment. We then identified the volar-most abductor pollicis longus tendon slip and released it from near its insertion. With the use of a small tendon stripper we extracted the tendon slip that now would be used for a tendon graft. We then placed the arthroscope back into the joint. With arthroscopic assistance we inserted the tendon graft between the metacarpal base and the lightly debrided trapezium (Fig. 4). Once the graft was in place, we noted that it filled the joint space nearly completely and the portal was closed with a polyglactin 910 deep suture (4-0 Vycril Rapide; Ethicon, Stollingen, Germany) stitch to avoid tendon extravasation. A short-arm thumb spica splint was placed and after 1 week the splint was changed for a short thumb spica cast for another 3 weeks.

At 2 months after surgery the right-sided pinch strength was 4.5 kgf and x-rays showed good positioning of the right basal joint (Fig. 5). During this time, however, deterioration of the left thumb was noted and the patient reported increasing pain. Radiographic studies of the left thumb basal joint showed bone-to-bone contact, large marginal osteophytes, and sclerosis. The patient had the same arthroscopic thumb CMC joint interposition arthroplasty and thermal capsule shrinkage 8 months after

the first procedure. Additionally the first extensor compartment was released. At the 8-week follow-up evaluation excellent pain relief was noted on the patient's left side. There was total absence of pain and the patient returned to all normal activities 1 year after the procedure on the right side and 4 months after the procedure on the left side (Fig. 6). The patient's grip strength was 51 kgf on the right side and 55 kgf lb on the left side. Right and left pinch strengths were 8 and 10 kgf respectively, which was stronger than the preoperative values, with complete resolution of symptoms.

Discussion

The anatomy of the trapeziometacarpal joint makes it susceptible to instability.¹¹ Most of the stability of this joint relies on the anterior oblique ligament.¹² Patients with Ehlers-Danlos syndrome show generalized ligament laxity. In the hand a lax anterior oblique ligament is stressed and stretched additionally by the action of the abductor pollicis longus; hence, simple activities of daily living may result in early subluxation, dislocation, and osteoarthritis.^{13,14}

Some investigators have proposed the use of arthrodesis of this joint in patients with Ehlers-Danlos syndrome to eliminate the joint laxity issue, thus preventing progressive degenerative changes on the

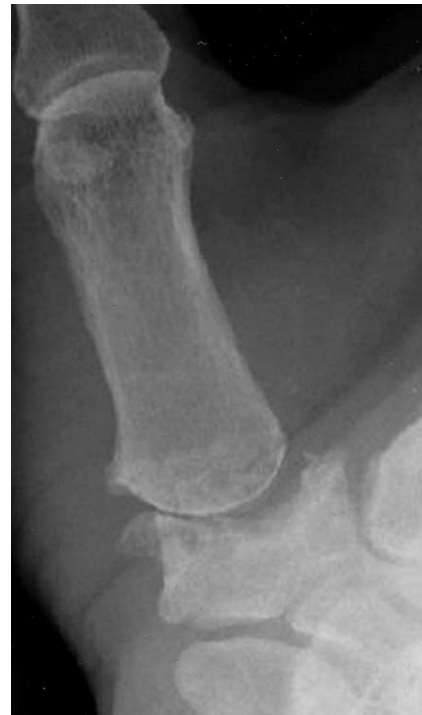

Figure 5. Postoperative radiograph showing the arthroplasty appearance with the newly created joint space.

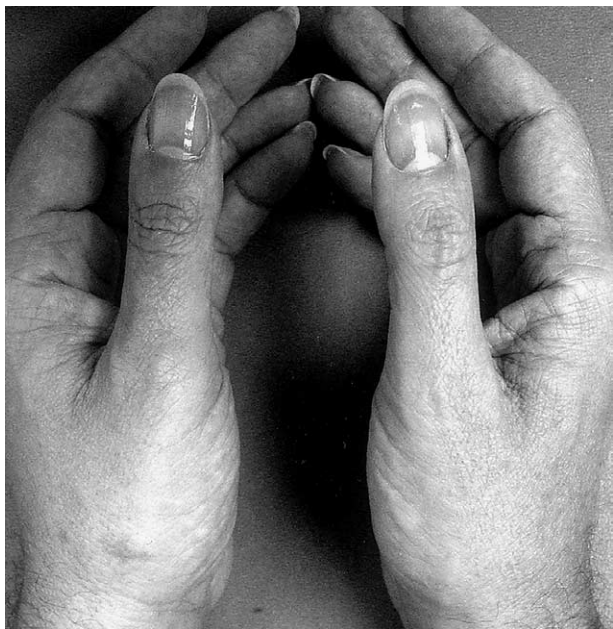

Figure 6. Late postoperative view of the thumbs showing the left thumb at 4 months after surgery and the right thumb at 1 year after arthroscopic interposition arthroplasty.

articular surfaces.^{5,6} Fusion of this joint, however, entails not only marked limitation of thumb motion but also the ability to lay the hand flat on a surface. The long-term success rates for thumb CMC tendon interposition arthroplasty have been encouraging.¹⁵⁻¹⁷ In view of the fact that our resection arthroplasty was successful it is likely that other resection arthroplasties also would be successful.

In this case, we did not have to perform an open ligament reconstruction to achieve stability. Arthroscopic thermal shrinkage of the CMC joint capsule initially was performed, followed by arthroscopic tendon interposition arthroplasty. The joint capsule was not violated at any point during the surgical procedure. When performing this arthroscopic reconstruction our first choice for the tendon graft to be used as a spacer is the palmaris longus. In this particular case the patient showed bilateral absence of this tendon and therefore we elected to take a slip of the abductor pollicis longus. Furthermore this patient was able to return to his previous activities without pain and at the 1-year follow-up evaluation his pinch strength and joint stability had improved. It is reasonable to wonder if the ligamentous laxity inherent to Ehlers-Danlos syndrome would compromise this patient's thumb CMC joints again at some point in the future. Should this be the case the previous tendon interposition arthroplasty would not preclude revision surgery. The outcome that was

sought for the tendon interposition arthroplasty in this patient, however, was to stabilize the thumb CMC joints and to minimize the bone-to-bone contact to relieve pain and restore strength and function, all of which are evident after the preliminary follow-up evaluation. Therefore we are encouraged by the results of this procedure as a treatment for osteoarthritic thumb basal joints in patients with Ehlers-Danlos syndrome.

References

1. Barron OA, Glickel SZ, Eaton RG. Basal joint arthritis of the thumb. *J Am Acad Orthop Surg* 2000;8:314-323.
2. Freedman DM, Eaton RG, Glickel SZ. Long-term results of volar ligament reconstruction for symptomatic basal joint laxity. *J Hand Surg* 2000;25A:297-304.
3. Eaton RG, Glickel SZ. Trapeziometacarpal osteoarthritis. Staging as a rationale for treatment. *Hand Clin* 1987;3:455-471.
4. Gamble JG, Mochizuki C, Rinsky LA. Trapeziometacarpal abnormalities in Ehlers-Danlos syndrome. *J Hand Surg* 1989;14A:89-94.
5. Kornberg M, Aulicino PL. Hand and wrist joint problems in patients with Ehlers-Danlos syndrome. *J Hand Surg* 1985;10A:193-196.
6. Moore JR, Tolo VT, Weiland AJ. Painful subluxation of the carpometacarpal joint of the thumb in Ehlers-Danlos syndrome. *J Hand Surg* 1985;10A:661-663.
7. Berger RA. A technique for arthroscopic evaluation of the first carpometacarpal joint. *J Hand Surg* 1997;22A:1077-1080.
8. Orellana MA, Chow JC. Arthroscopic visualization of the thumb carpometacarpal joint: introduction and evaluation of a new radial portal. *Arthroscopy* 2003;19:583-591.
9. Menon J. Arthroscopic management of trapeziometacarpal joint arthritis of the thumb. *Arthroscopy* 1996;12:581-587.
10. Eaton RG, Lane LB, Littler JW, Keyser JJ. Ligament reconstruction for the painful thumb carpometacarpal joint: a long-term assessment. *J Hand Surg* 1984;9A:692-698.
11. Kauer JMG. Functional anatomy of the carpometacarpal joint of the thumb. *Clin Orthop* 1987;220:7-13.
12. Gunther SF. The carpometacarpal joints. *Orthop Clin North Am* 1984;15:259-277.
13. Cooney WP III, Chao EYS. Biomechanical analysis of static forces in the thumb during hand function. *J Bone Joint Surg* 1977;59A:27-36.
14. Zancolli EA, Ziadenberg C, Zancolli E Jr. Biomechanics of the trapeziometacarpal joint. *Clin Orthop* 1987;220:14-26.
15. Eaton RG, Glickel SZ, Littler JW. Tendon interposition arthroplasty for degenerative arthritis of the trapeziometacarpal joint of the thumb. *J Hand Surg* 1985;10A:645-654.
16. Barron OA, Eaton RG. Save the trapezium: double interposition arthroplasty for the treatment of stage IV disease of the basal joint. *J Hand Surg* 1998;23A:196-204.
17. Tomaino MM, Pellegrini VD Jr, Burton RI. Arthroplasty of the basal joint of the thumb. Long-term follow-up after ligament reconstruction with tendon interposition. *J Bone Joint Surg* 1995;77A:346-355.