

REVIEW ARTICLE

Arthroscopy of the Trapeziometacarpal and Metacarpophalangeal Joints

Alejandro Badia, MD

From Miami Hand Center, Miami, FL; Baptist Hospital, Miami, FL; and the DaVinci Learning Center, Miami, FL.

Indications for small joint arthroscopy in the hand remain poorly understood. This is due to a paucity of articles discussing these techniques in the literature, as well as inadequate hands-on training in the pearls and pitfalls regarding this application within the routine “scope” of hand surgery. Despite the fact that small joint arthroscopes have been available for more than a decade, hand surgeons have been slow to adopt this technique for the treatment of both traumatic and degenerative conditions involving the thumb and the digital metacarpophalangeal joints. An arthroscopic classification for basal joint osteoarthritis provides additional clinical information and can direct further treatment depending on the stage of disease. This article will also review the brief history of trapeziometacarpal arthroscopy and provide insight as to how this technique can be incorporated into a treatment algorithm in managing this common affliction. Metacarpophalangeal joint arthroscopy is even less commonly utilized, while traumatic and overuse injuries are frequently seen in the thumb and constitute ideal indications in certain scenarios. Painful conditions affecting the metacarpophalangeal joints of the fingers are less commonly seen, yet the small joint arthroscope presents a much clearer picture of the pathology compared with other imaging techniques or even open, potentially deleterious surgery. The application of this technology to the smaller joints will soon make the treating surgeon realize that a myriad of pathologies are readily visible and can augment treatment, as well as diagnosis. Similar to the wrist, small joint arthroscopy may one day supplant imaging techniques such as magnetic resonance imaging or computed tomography for establishing an accurate diagnosis. (J Hand Surg 2007;32A: 707–724. Copyright © 2007 by the American Society for Surgery of the Hand.)

Key words: Arthroscopy, metacarpophalangeal joint, trapeziometacarpal joint, treatment options, technique.

Osteoarthritis of the thumb trapeziometacarpal joint is a common clinical problem as well as a perplexing challenge because of a myriad of treatment options. That so many different surgical options exist for this condition attests to the fact that none of them has an optimal success rate, or perhaps it may be that the majority of treatment options work to the satisfaction of the surgeon; hence, the clinician continues to use his favorite technique despite the fact that this may not be the most appropriate method for a particular stage of disease. One thing is indisputable: Basal joint osteoarthritis of the thumb has many different clinical presentations, and one technique cannot be used for all of the different stages and a patient’s individual needs. When conservative treatment has been exhausted, there is a wide range

of surgical options that should be tailored to the individual patient.

The early stages of basal joint osteoarthritis are most commonly seen in middle-aged women. This is discussed in the literature in many instances but rarely is a solution given to the management of these usually active patients. Anti-inflammatory drugs, splinting, and corticosteroid injections serve only as palliative measures with none of these altering joint mechanics or affecting the articular surface itself in any manner. Moreover, use of injectable steroids can accelerate cartilage loss and worsen capsular attenuation. Only the mildest cases of transient synovitis will escape the inevitable progressive loss of cartilage and, hence, the need for surgical treatment if the patient indeed wants a definitive solution. After the

relatively unimportant distal interphalangeal joint, the thumb carpometacarpal joint remains the most common location for osteoarthritis in the hand. It is also the most critical for hand function. The argument has been made that man's evolution has been largely due to the increased range of motion and function as a consequence of the thumb basal joint and has led to the progressive use of tools in hominid evolution. Treatment of this functionally important joint remains a priority for the hand surgeon, and it is important to use the wide variety of surgical techniques to optimally manage this condition.

Classically, the basal joint has been treated by surgical means only when conservative options have been exhausted. The principal option has been, and remains, some type of open resectional arthroplasty. Although good results are demonstrated in the literature in many different studies and using a variety of techniques, it remains clear that this is a surgically aggressive procedure because resection of an entire carpal bone is required to achieve pain relief. This certainly makes good sense in the most advanced cases where the trapezium is typically flattened or has severe deformity including deforming marginal osteophytes, but earlier stages demand a more conservative option that allows for future interventions if the primary treatment is not successful. Other less aggressive options include a hemiresection with tendon interposition arthroplasty or an Artelon spacer, which can provide excellent pain relief but often lead to some weakness of grip. Arthrodesis is often indicated in the younger manual laborer but has disadvantage of limitation of motion. Joint arthroplasty, like in any other joint in the body, has the added risk of failure of the implant, whether this be silicone or of metallic and plastic components. This is certainly not a good option for the younger, high-demand patients but is a suitable option for elderly, low-demand patients.

History

The advent of small joint arthroscopic technology has allowed us to apply the concept of minimally invasive surgery to smaller joints including the wrist, ankle, and now the smaller joints of the hand. Y-C. Chen's classic article in 1979 on arthroscopy of the wrist and finger joints discussed the feasibility of performing small joint arthroscopic procedures using the Watanabe no. 24 arthroscope as early as 1970.¹ However, in Chen's article there was surprisingly no mention of arthroscopy of the thumb trapeziometacarpal joint, despite the fact that this may be the

greatest small joint application of arthroscopy. In Chen's article, there was a detailed description of arthroscopy of the wrist, metacarpophalangeal joints, and even the small interphalangeal joints. Nevertheless, the common applicability of this technology to such a ubiquitous clinical scenario may prove to be its greatest contribution.

The first clinical article in the literature on basal joint arthroscopy was written by J. Menon in the *Journal of Arthroscopic and Related Surgery* in 1996.² This article, entitled "Arthroscopic Management of Trapeziometacarpal Joint Arthritis of the Thumb," described arthroscopic partial resection of trapezium as well as an interpositional arthroplasty using autogenous tendon graft, Gore-Tex, or fascia lata allograft as interposing substances. In this article, it was obvious that the patients had a more advanced stage of arthritis, though Menon's own clinical stages presented the addition of metacarpal base subluxation as criteria for the advanced stages, and he limited the indications to less than stage 4 disease. In his classification, this stage correlates with metacarpal base subluxation greater than one-third of its diameter and adduction contracture. No mention was made whether very early stages of basal joint arthritis were treated with this innovative technique. In fact, my hope is to demonstrate that the utility of arthroscopy may be greatest in the earlier stages. The goal of Dr. Menon's procedure was to avoid destabilizing the basal joint by avoiding an open arthrotomy and performing the hemitrapeziectomy, which had already been described as an open procedure, and interposing the material with the assistance of an arthroscope. Three-quarters of the patients had complete pain relief in his series of 25 patients. The results were comparable with the open technique, but he described several advantages attributed to its minimally invasive nature. For one, it is simply less invasive and, hence, has implicit advantages such as a lesser chance of injuring the radial sensory nerve and that postoperative pain is much less. However, the less obvious advantage is that arthroscopy of the trapeziometacarpal joint can detect any articular changes long before they would be noted through routine radiographs. This enables us to treat basal joint osteoarthritis in much earlier stages, and the clinical indication for surgery could simply be pain, not the stage of radiographic disease. This presents a great opportunity and allows us to use the arthroscope as a tool for treating younger and more active patients with the early stages of basal joint arthritis.

One year later, Richard Berger from the Mayo

Clinic presented his experience of 1st carpometacarpal joint arthroscopy in a technique article in the *Journal of Hand Surgery* in 1997.³ He believed that small joint arthroscopic technology presented several advantages over a standard open arthrotomy, where joint visualization would be difficult because of the depth of the joint and that one could avoid disruption of the critical ligamentous structures that he so aptly described. After his clear description, he briefly mentioned 12 arthroscopic procedures that he had performed since 1994 with a variety of clinical scenarios including acute Bennett fractures of the thumb. He noted that there was an excellent visualization and no complications with this surgery. At that time, the indications for 1st carpometacarpal (CMC) joint arthroscopy were not clearly defined, but he noted that it was obviously an excellent alternative to arthrotomy for visualizing the anatomy. This article followed an instructional lecture and demonstration that he had performed at the Orthopaedic Learning Center during the wrist arthroscopy course, which I had the pleasure of attending. Despite its infancy, it was obvious to me at that time that basal joint arthroscopy would have a wide range of application and clinical utility within this spectrum of pathology. Soon after this landmark article was published, Menon presented a letter to the editor indicating the fact that he had actually published the clinical use of arthroscopy in the basal joint in a previous article.⁴ In Dr. Berger's reply, he diplomatically noted that his technique was developed independently as it was presented as an instructional course in 1995, and the common delays in publishing led to this overlap with Dr. Menon's publication.⁵ It is clear that both of these authors have made an invaluable contribution to our treatment armamentarium for the basal joint. Further, clinical utility was validated in the article by Osterman et al presented in *Arthroscopy* in 1997 where they defined 2 groups of patients, traumatic and degenerative, who would benefit from use of this imaging technology.⁶ They, too, believed it had a promising place in the treatment of both acute and chronic conditions of the thumb carpometacarpal joint. They were the first to mention that arthroscopy may allow for appropriate staging of the degree of trapezial involvement and has particular application in the younger patient.

Hence, it is obvious that arthroscopy of the thumb carpometacarpal joint allows us to appropriately stage the extent of cartilage degeneration and subsequently determine therapeutic options. I maintain that the arthroscope can be used not only for treat-

ment of earlier stages but also in advanced stages as Menon so well described.

The goal of this article, among many, is to describe an arthroscopic classification of the thumb carpometacarpal joint and determine a treatment algorithm based on this staging system. Whether the clinician decides to use arthroscopy definitively for treatment remains an option. Before we expand on the disease staging that arthroscopy allows, we must better understand the ligamentous anatomy and its functional significance as related to biomechanics. However, there can be no argument that the arthroscope gives us the true extent of basal joint disease.

Functional Anatomy

Arthroscopy of the thumb carpometacarpal joint has little relevance if the treating surgeon does not understand the ligamentous anatomy. This has been described extensively through cadaver dissections, and over time we will be able to better correlate these open landmarks with the arthroscopic findings. The pioneering description of the trapeziometacarpal ligaments dates way back to 1742 when Weitbrecht described these ligaments in a rudimentary fashion in his book *Syndesmology*.⁷ This book was reprinted in 1969. Since then, a variety of authors have further described the details of this anatomy with the most detailed work coming from Bettinger and others at the Mayo Clinic in their article in 1999.⁸ They described a total of 16 ligaments, including ligaments between the metacarpal and trapezium as well as 2 ligaments attaching the trapezium to the second metacarpal and separate stabilizers for the scaphotrapezial and trapezoidal joints. It was their conclusion that this complex of ligaments functions as tension bands to prevent instability from cantilever bending forces placed upon the trapezium by the act of pinch. This was a critical concept because extremely large loads are transferred to the trapezium, and there is no fixed base of support because the scaphoid is an extremely mobile carpal bone. It is the attenuation and pathologic function of these ligaments that may indeed lead to the common scenario of basal joint arthritis. Based on improved ligamentous understanding, Van Brenk et al suggested that the dorso-radial collateral (RCL) ligament was, in fact, the most important ligament in the prevention of trapeziometacarpal subluxation.⁹ This was determined by a cadaveric study where serial sectioning of 4 separate ligaments determined that RCL was the most critical in preventing dorsoradial subluxation. Zancolli et al, in his landmark *Atlas of Surgical Anatomy*

of the Hand, supports this concept but also adds the controversial premise that aberrant slips of the abductor pollicis longus may cause an excessive compressive force of the dorsoradial aspect of trapeziometacarpal joint leading to arthrosis.¹⁰ He believed the underlying ligamentous laxity may be due to underlying variations in an individual person's ligamentous laxity or a hormonal predisposition that may explain the increased incidence in the female gender. These theories led to a greater understanding of the causes of basal joint arthritis, and arthroscopic visualization may in the future lend further credence to these theories. Xu et al indicated that the trapeziometacarpal joint is smaller and less congruous in women and may also have a thinner layer of hyaline cartilage, suggesting this is a cause for the higher incidence of basal joint osteoarthritis in women.¹¹ This, too, has been my experience and suggests that the greatest applicability of arthroscopy may be in younger women, who present with this disease at a much earlier age and have, implicitly, less surgical treatment options.

Pellegrini in *Hand Clinics* 1979 continued to affirm that the volar beak ligament plays an important role in preventing dorsal translation of the metacarpal during common functional activities.¹² This ligament as well as the dorsoradial ligament both are clearly visualized via arthroscopy, and direct intervention is now feasible. His hypothesis is that there are attritional changes in the beak ligament at the metacarpal insertion site, and this insertion zone may be particularly sensitive to estrogen-type compounds. This lends further support to the genetic predisposition of this condition. Arthroscopically, I have confirmed this, having noted particular cartilage loss at the insertion of the volar beak ligament on the deep metacarpal base in the early stages when the remainder of the hyaline cartilage appears normal. Many of these anatomic, clinical, as well as biomechanical concepts have been further defined by Bettinger and Berger in their work on the functional ligamentous anatomy of this joint.¹³ They did note that the arthroscopic anatomy is much less complicated because only a limited number of structures are able to be seen from the interior perspective. For the first time, they outlined which of the 2 common portals would lead to clear visualization of corresponding ligaments. Although they discussed optimal viewing, the reader should note that the small size of this joint allows one to visualize the majority of the surface simply by a change in the viewing direction and the angulation that the arthroscope is held in. Recently,

other authors have described new portals to help further define the topographic anatomy of this joint. Orellana and Chow described a radial portal that they found was safer because of its distance from the radial artery and branch of the superficial radial nerve, moreover, it allowed better triangulation.¹⁴ For this reason, Walsh et al also described another portal, the thenar portal, which was much more volar, actually passing through the thenar muscles to allow for improved triangulation and visualization of the joint via a presumably safer location.¹⁵ A further advantage of this portal is that it does not violate the deep, anterior oblique ligament, which, as also pointed by Bettinger and Berger, serves as the major restraining structure against dorsal subluxation.¹³ Gonzalez et al also described portals for better visualization.¹⁶ These newer portals suggest that thumb CMC arthroscopic surgery is in a state of evolution and hopefully will allow us to better understand arthritis at this level. Again, careful documentation of these structures over time may allow arthroscopy to further elucidate the cause of dorsal subluxation as a factor in basal joint arthritis.

Culp and Rekant were the first clinicians to suggest that arthroscopic evaluation; debridement, and synovectomy “offer an exciting alternative for patients with Eaton and Littler stages I and II arthritis.”¹⁷ They described radiofrequency “painting” of the capsule of the trapeziometacarpal joint to stabilize the critical volar ligaments that may cause dorsal subluxation and, consequently, arthrosis of the basal joint. They also mention that if the majority of the trapezoidal surface is abnormal, then at least one-half of the distal trapezium should be resected with an arthroscopic burr. This indicates that a more advanced stage of arthrosis is present and does not necessarily support its use in the early stages. In fact, their short-term results described in this paper followed arthroscopic hemi or complete trapeziectomy coupled with electrothermal shrinkage. They had nearly 90% excellent or good outcome in 22 patients with a moderate follow-up. They did make the critical point that “no bridges had been burned” because patients who have the arthroscopic procedure can always serve as suitable future candidates for more aggressive complete excisional trapezoidal arthroplasty by open means. They concluded that debridement and thermal capsular shrinkage is a potentially good treatment for early arthritis of the basal joint. It is now well apparent via these multiple articles describing the arthroscopic findings that a more comprehensive staging system is necessary to dictate treatment.

Table 1. Badia Arthroscopic Classification of Basal Joint Arthritis

Stage	Arthroscopic Changes
1	<ul style="list-style-type: none"> • Intact articular cartilage • Disruption of the dorsoradial ligament and diffuse synovial hypertrophy • Inconsistent attenuation of the AOL
2	<ul style="list-style-type: none"> • Frank eburnation of the articular cartilage on the ulnar third of the base of 1st metacarpal and central third of the distal surface of the trapezium • Disruption of the dorsoradial ligament plus more intense synovial hypertrophy • Constant attenuation of the AOL
3	<ul style="list-style-type: none"> • Widespread, full-thickness cartilage loss with or without a peripheral rim on both articular surfaces • Less severe synovitis • Frayed volar ligaments with laxity

All of the clinical results in the studies to date have focused on more advanced osteoarthritis and have all discussed the results after an arthroscopic-assisted hemitrapeziectomy. It is perhaps in the patient whose trapezium is largely spared that arthroscopy may find its greatest utility. A novel classification that I have devised to dictate treatment for the respective stage provides the basic framework for the arthroscopic evaluation and effective management of the different stages of this disabling condition (Table 1).¹⁸

Indications for Basal Joint Arthroscopy

In my practice over the past 11 years, the vast majority of patients with the diagnosis of thumb basal joint arthritis who did not improve after conservative treatment had arthroscopy for further evaluation of the joint status and surgical treatment. The disease was staged radiographically according to Eaton's criteria.¹⁹ The notable exceptions were in patients with advanced Eaton stage 4 arthritis who then had a trapezial excisional suspensionplasty using a slip of abductor pollicis longus. Stage 4 patients with only mild scaphotrapezialtrapezoid (STT) changes were still treated with arthroscopy. Another exception was much older, low-demand patients who did well using a cemented total joint arthroplasty as this required almost no immobilization and minimal therapy. Many of these patients displayed an adduction contracture, and the open arthroplasty that permitted an adductor release and a metacarpophalangeal (MCP) volar capsulodesis was often needed in cases with severe swan-neck deformity. The last exception was the rare young, male laborer who had a trapeziometacarpal joint arthrodesis. This indication has been well substantiated in the literature.²⁰

Surgical Technique

The arthroscopic procedure is performed under wrist block regional anesthesia with tourniquet control. A single Chinese finger trap is used on the thumb with 5–8 lb of longitudinal traction. A shoulder holder, rather than traction tower, is used to easily facilitate fluoroscopic intervention. The trapeziometacarpal (TMC) joint is then detected by palpation. The incision for the 1-R (radial) portal, which is used for proper assessment of the dorsoradial ligament (DRL), posterior oblique ligament (POL), and ulnar collateral ligament (UCL), is placed just volar to the abductor pollicis longus (APL) tendon. The incision for the 1-U (ulnar) portal, which allows better evaluation of the anterior oblique ligament (AOL) and UCL, is made just ulnar to the extensor pollicis brevis (EPB) tendon. Joint distention is achieved by injecting 2–3 mL of normal saline. A short-barrel, 1.9-mm, 30° inclination arthroscope is used for complete visualization of the TMC joint surfaces, capsule, and ligaments, and then appropriate management is performed as dictated by the pathology found. A full radius mechanical shaver with suction was used in all cases, particularly for initial debridement and visualization. Many cases were augmented with radiofrequency ablation in order to perform a more thorough synovectomy. Radiofrequency was also used to perform chondroplasty in cases with focal articular cartilage wear or fibrillation. Ligamentous laxity and capsular attenuation were treated with thermal capsulorrhaphy using a radiofrequency shrinkage probe. We were careful to avoid thermal necrosis, and, therefore, a stripping technique was used to tighten the capsule of lax joints. Although use of radiofrequency is relatively new, we can gain further understanding by prior basic science studies and the clinical application in other joints. Prior to elaborating further on the details of TMC arthroscopy, it is important to understand the application of radiofrequency technology to this small joint, as well as the later discussed MCP arthroscopy.

Application of Radiofrequency in Small Joint Arthroscopy

Orthopedic surgeons have benefited from the use of radiofrequency in a variety of procedures during the past decade. It is only now that we are realizing that it may have some detrimental effects, and it is important to look at this technology more critically.

Nevertheless, as with any new technique, judicious use of this technology may allow for stabilization of the joint capsule in a variety of clinical scenarios. Shoulder instability has been treated by a variety of authors using radiofrequency to stabilize the joint, particularly in those patients with global instability who classically have not been considered good operative candidates. It has also been used in the knee extensively, but there has been minimal mention in the literature of its application in the joints of the hand. Obviously, this is coupled with the fact that arthroscopy of the trapeziometacarpal joint and, furthermore, the metacarpophalangeal joint has been scant in the literature.

Radiofrequency has had many medical applications since its initial use in the 1800s for creating lesions in brain tissue. It has also been used in cardiology, oncology, and colorectal surgery. Lopez and colleagues first demonstrated the effect of radiofrequency energy on the ultrastructure of joint capsular collagen in a histologic study.²¹ They noted that similar applications had been used with a nonablative laser energy in orthopedics but that radiofrequency offered several advantages over the use of a laser. Not only is it less expensive and safer, but also these units are much smaller and easily maneuverable in application to arthroscopic techniques. Initial studies on a sheep joint indicated that the thermal effect was characterized by the fusion of collagen fibers without tissue ablation, charring, or even crater formation. There was a linear relationship between the degree of collagen fiber fusion and increasing treatment temperature. This indicates that the technology must be treated with respect to avoidance of aggressive use. It was postulated that the coagulated tissue mediates a mild inflammatory reaction that leads to the degradation and replacement of the affected capsule with a denser tissue. This would obviously help to stabilize the joint and thus have particular application in the trapeziometacarpal joint based on previous discussions in this article. In a later study, Hecht and colleagues also looked specifically at effect of monopolar radiofrequency energy on the joint capsular properties.²² They concluded that monopolar radiofrequency caused increased capsular damage in the immediate area and depth that correlated with the wattage used. The heat production increased linearly with the duration of application. The arthroscopic lavage could protect the synovial layer from permanent damage as seen in sheep. These findings suggest that radiofrequency probes must be used with adequate fluid lavage as well as for short durations and

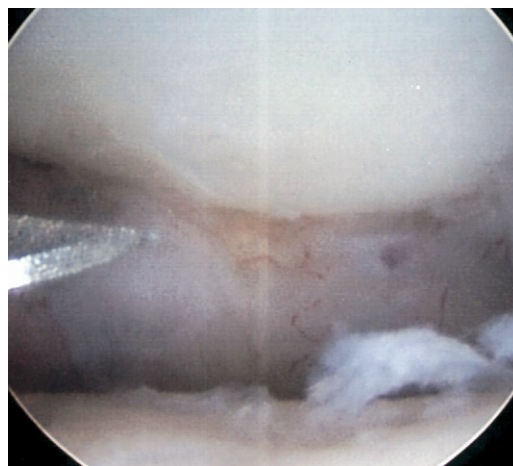


Figure 1. Arthroscopic view showing arthroscopic stage 2 basal joint arthritis. Note the loss of cartilage deep on the metacarpal base and central part of the distal trapezium.

with the minimal wattage necessary to achieve the desired effect. I refer specifically to monopolar radiofrequency, as it is a common understanding among orthopedic surgeons that monopolar radiofrequency causes less heat production than bipolar modalities. This is particularly important to the hand surgeon because there are close neurovascular structures directly overlying the joint capsule in the small joints compared with the knee or shoulder. Further understanding may be gleaned in the future if a direct clinical comparison can be made with monopolar versus bipolar radiofrequency treatments in the small joints.

Arthroscopic Staging

Arthroscopic stage 1 patients (Table 1) are characterized by diffuse synovitis but with minimal, if any, articular cartilage loss. Ligamentous laxity, particularly the entire volar capsule, is a frequent finding. This presentation is relatively uncommon, as most patients present late, having suffered with symptoms for a long period or referred at a delayed time, once conservative means have been exhausted. These patients have synovectomy, both mechanical and by radiofrequency, with occasional shrinkage capsulorraphy performed depending on findings. The joint is then protected in a thumb spica cast from 1 to 4 weeks depending on the extent of capsular laxity. More unstable joints require longer immobilization in order to achieve joint stability and presumably slow the progression of articular cartilage degeneration.

Arthroscopic stage 2 patients are characterized by focal wear of the articular surface on the central to

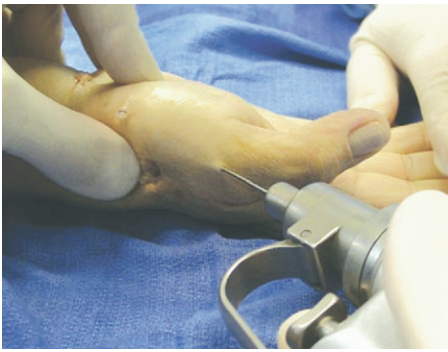

Figure 2. Centralizing K-wire fixation of the metacarpal base dorsoradial osteotomy.

dorsal aspect of the trapezium (Fig. 1). In my opinion, this represents an irreversible process and requires a joint modifying procedure in order to alter the vector forces across the joint. After synovectomy, debridement, and occasional loose body removal, the joint was reassessed to determine the extent of instability and capsular attenuation. A shrinkage thermal capsulorraphy was performed in most of the cases, with chondroplasty frequently performed to anneal the cartilage borders. The arthroscope was then removed and the ulnar portal extended distally to expose the metacarpal base. A dorsoradial closing wedge osteotomy, similar to Wilson's original technique,²³ was then performed to place the thumb in a more extended and abducted position. This is to minimize the tendency for metacarpal subluxation and to change the contact points of worn articular cartilage. The osteotomy is protected by a single oblique K-wire that is also placed across the 1st CMC joint in a reduced position (Fig. 2).

This not only allows for healing of the osteotomy in the corrected position but also leads to a correction of the metacarpal subluxation so often seen in this stage. A thumb spica cast protects this during healing, and the wire is removed at 5 weeks after operation. Only arthroscopy can determine the optimal indications for this osteotomy, which has demonstrated good results in the past and in a more recent article by Tomaino.²⁴ Late follow-up on my patients has demonstrated that the metacarpal remains "centralized," and it is unclear if the capsular shrinkage played a role versus the alteration of biomechanics by use of osteotomy.

Arthroscopic stage 3 is characterized by much more diffuse trapezial articular cartilage loss (Fig. 3). The metacarpal base can also be devoid of cartilage to varying degrees. Arthroscopic findings indicate that this is not a joint worth preserving, and a simple

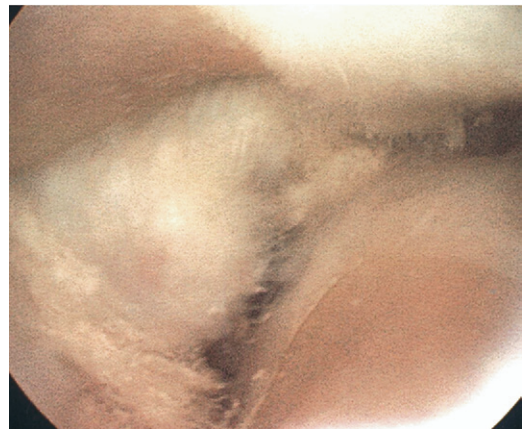


Figure 3. Arthroscopic view showing arthroscopic stage 3 basal joint arthritis. Note the diffuse loss of cartilage on the distal trapezium.

debridement or even accompanying osteotomy would not give a good long-term result in this case. An arthroscopic hemitrapeziectomy is then performed by burring away the remaining articular cartilage and also removing subchondral bone down to a bleeding surface. This serves to not only increase the joint space but also to allow for bleeding that will form an organized thrombus adhering to an interposed tendon graft or other interposed substance. This tendon graft, either palmaris longus or the volar slip of APL, is inserted via a portal similar to the technique as proposed by Menon.² A thumb spica cast in a palmar abducted position is then maintained for 4 weeks followed by hand therapy to focus on pinch strengthening. Artelon material for interposition presents a good option to avoid the need for tendon procurement (Figs. 4, 5). Minami et al in their study using silicon rubber interposition arthroplasty strongly condemned the procedure and attributed

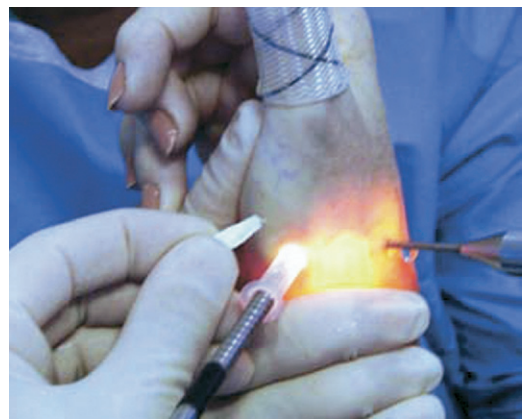

Figure 4. Photograph showing the technique for arthroscopic insertion of the Artelon spacer in the 1st CMC joint.

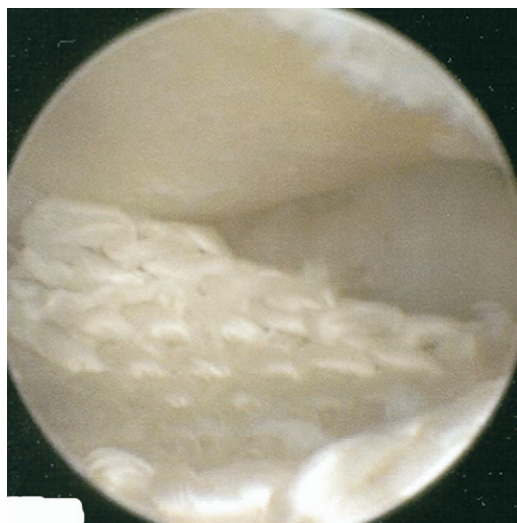


Figure 5. Arthroscopic view showing Artelon spacer well placed in the 1st CMC joint.

long-term failures to silicon synovitis and implant breakage.²⁵ Nilsson et al in their prospective study comparing tendon interposition arthroplasty and Artelon spacer have concluded that Artelon is a nonre-active material that markedly improved tripod and key pinch strengths compared with tendon interposition arthroplasty.²⁶

Stage 3 can also be treated by a traditional open excisional arthroplasty,^{27–30} arthrodesis,²⁰ or total joint replacement,^{31,32} depending on the surgeon's preference. The Artelon material can also be used in open indications where the wings of the implant are used to stabilize the joint, therefore being a good option for advanced arthrosis where subluxation and joint stability is an issue. More aggressive options are still feasible, as even open use of this implant does not necessitate complete trapezial excision.

Arthroscopic and Radiographic Correlation

The most consistent arthroscopic findings in the group of patients who displayed radiographic changes compatible with stage 1 of the disease included fibrillation of the articular cartilage on the ulnar third of the base of the 1st metacarpal, disruption of the dorsoradial ligament, and diffuse synovial hypertrophy. A less reliable discovery was attenuation of the AOL.

Regular arthroscopic findings noted in patients classified as having stage 2 arthritis were frank eburnation of the articular cartilage of the ulnar third of the metacarpal base and central third of the distal surface of the trapezium, disruption of the dorsoradial ligament, more noticeable attenuation of the

AOL, and more intense synovial hypertrophy (Fig. 1). Most of the patients with this arthroscopic stage also presented as stage 2 radiographically, but on occasion patients deemed stage 1 may actually have more advanced findings once the joint is truly assessed. Herein lies one of the great advantages of fiberoptic technology as it allows true assessment of the joint that no imaging procedure can challenge. Only the rare case demonstrated less cartilage wear than supposed on the plain film. Consequently, radiographic stage 3 rarely is considered stage 2, but that does greatly influence and expand the treatment options. Because this stage may have the most clinical impact on our method of treatment, due to lack of good options, it is important to review the patient outcomes for arthroscopic stage 2 disease.

Arthroscopic Stage 2 Results

A retrospective assessment evaluated arthroscopic stage 2 patients with adequate follow-up in a selected 3-year period. Forty-three patients (38 female and 5 male) were arthroscopically diagnosed as having stage 2 basal joint osteoarthritis of the thumb between 1998 and 2001. All the procedures were performed by me with follow-up data generated by visiting fellows for objectivity. The average age was 51 years (range, 31–69 years). The right thumb was involved in 23 patients and the left in 20. There was no improvement after a minimum 6 weeks of conservative treatment under my direction. The surgical procedure consisted of arthroscopic synovectomy, debridement, occasional thermal capsulorrhaphy followed by an extension-abduction closing wedge osteotomy in all cases. A 1.4 mm (0.045-in) K-wire provided stability to the osteotomy site, and a short arm thumb spica cast was used for 4–6 weeks until pin removal. The average follow-up was 43 months (range, 24–64 months).

Consistent arthroscopic findings in the selected group were frank eburnation of the articular cartilage of the ulnar third of the base of the 1st metacarpal and central third of the distal surface of the trapezium, disruption of the dorsoradial ligament, attenuation of the anterior oblique ligament, and synovial hypertrophy. The osteotomy healed within 4–6 weeks in all the cases. Radiographic studies at final follow-up depicted maintenance of centralization of the metacarpal base over the trapezium and no progression of arthritic changes in 42 patients. Average range of thumb MCP joint motion was 5°–50° and thumb opposition reached the base of the small finger in all cases. The average pinch strength was 9.5 lb

(73% from nonaffected side). At final follow-up, patients were evaluated by Buck-Gramcko score, which takes into account both the subjective as well as objective outcomes.³³ The mean total Buck-Gramcko score in our series was 48.4 ("Good Outcome"). The constant pain in one of the patients was due to progressive osteoarthritis after the procedure. She did not respond to steroid injections and finally had to have arthroscopic-assisted hemitrapeziectomy due to progressive arthritis. A longer follow-up will be later obtained to better assess the long-term utility of this technique and to publish these findings specifically in stage 2 patients.

Arthroscopy in patients who had radiographic features of stage 3 and 4 generally display widespread full-thickness cartilage loss with or without a peripheral rim on both articular surfaces, less severe synovitis, and frayed volar ligaments with laxity (Fig. 3). This clearly constitutes arthroscopic stage 3, and the treatment options here are quite varied. The arthroscope can be removed and the most appropriate open procedure performed. I prefer the arthroscopic interposition arthroplasty in most of the cases. Based on the above findings and clinical experience, I have recently proposed the arthroscopic classification and treatment algorithm delineated in Table 1 and Figure 6.

Trapeziometacarpal Arthroscopy: Clinical Use

Clinical assessment and radiographic studies used to be the only tools available for the selection of treatment modalities for thumb CMC arthritis.^{34,35} Eaton and Glickel proposed a staging system for this disease that has been widely applied.¹⁹ Later, Bettinger et al³⁶ described the trapezium tilt as a parameter to predict further progression of the disease. They found that in advanced stages (Eaton 3 and 4), the trapezium tilt was high ($50^\circ \pm 4$; normal: $42^\circ \pm 4$). Barron and Eaton concluded that there appears to be no indication for magnetic resonance imaging (MRI), tomography, or ultrasonography in the routine evaluation of basal joint disease.³⁷

Although I believe that a radiographic classification is important for a stepwise interpretation of the progression of this entity, my experience has demonstrated instances when it is very difficult to make an accurate diagnosis of the extent of disease based solely on radiographic features. Recent advances in arthroscopic technology have allowed complete examination of smaller joints throughout the body with minimal morbidity.¹ Moreover, arthroscopy has already proved to be reliable for direct evaluation of

the 1st carpometacarpal joint as previously discussed.³

In early stages of thumb basal joint arthritis; for instance, in Eaton stage 1, it is very common to find essentially normal radiographic studies despite the presence of painful limitation of the thumb. In my experience, I have found that this group of patients displays mild to moderate synovitis that could benefit from a thorough joint debridement combined with thermal shrinkage of the ligaments to enhance the stability. This, of course, after assuming they have not responded well to conservative treatment including splinting, nonsteroidal anti-inflammatory drug use, and corticosteroid injection. This stage is typically seen in middle-aged women who are often not suitable candidates for more aggressive procedures.³⁵ Arthroscopic treatment provides a particularly good option for this ubiquitous subset of patients.

Tomaino concluded that 1st metacarpal extension osteotomy is a good indication for Eaton stage 1.²⁴ This invasive procedure may not be necessary in the occasional patient who has arthroscopy at an early time and demonstrates no focal cartilage loss. Future studies may indicate that synovectomy, and perhaps thermal capsulorrhaphy, may avoid progression of disease and the need for a mechanical intervention. However, the arthroscopic findings that I previously described for arthroscopic stage 2 of the disease demand a joint modification such as osteotomy to minimize the chance of further articular degeneration. My retrospective study indicates that this approach is efficacious with only 1 out of 43 thumbs developing progressive arthritis requiring further surgery.

There remains little doubt that if complete articular cartilage loss is the arthroscopic scenario, the logical next step is to perform some type of trapezium excision with interposition arthroplasty. Menon described a technique demonstrating arthroscopic debridement of the trapezium articular surface and interposition of autogenous tendon, fascia lata or Gore-Tex patch into the CMC joint in patients with stage 2 and 3 with excellent results.² I have demonstrated that this arthroscopic technique is even effective in patients with underlying severe ligamentous laxity, as in Ehler-Danlos syndrome.³⁸ Newer techniques may allow the arthroscopic insertion of Arton, which has proved successful with open techniques and confirmed histologically.²⁵ In either case, complete excision of the trapezium may not be desirable, particularly in younger patients. The stage 3

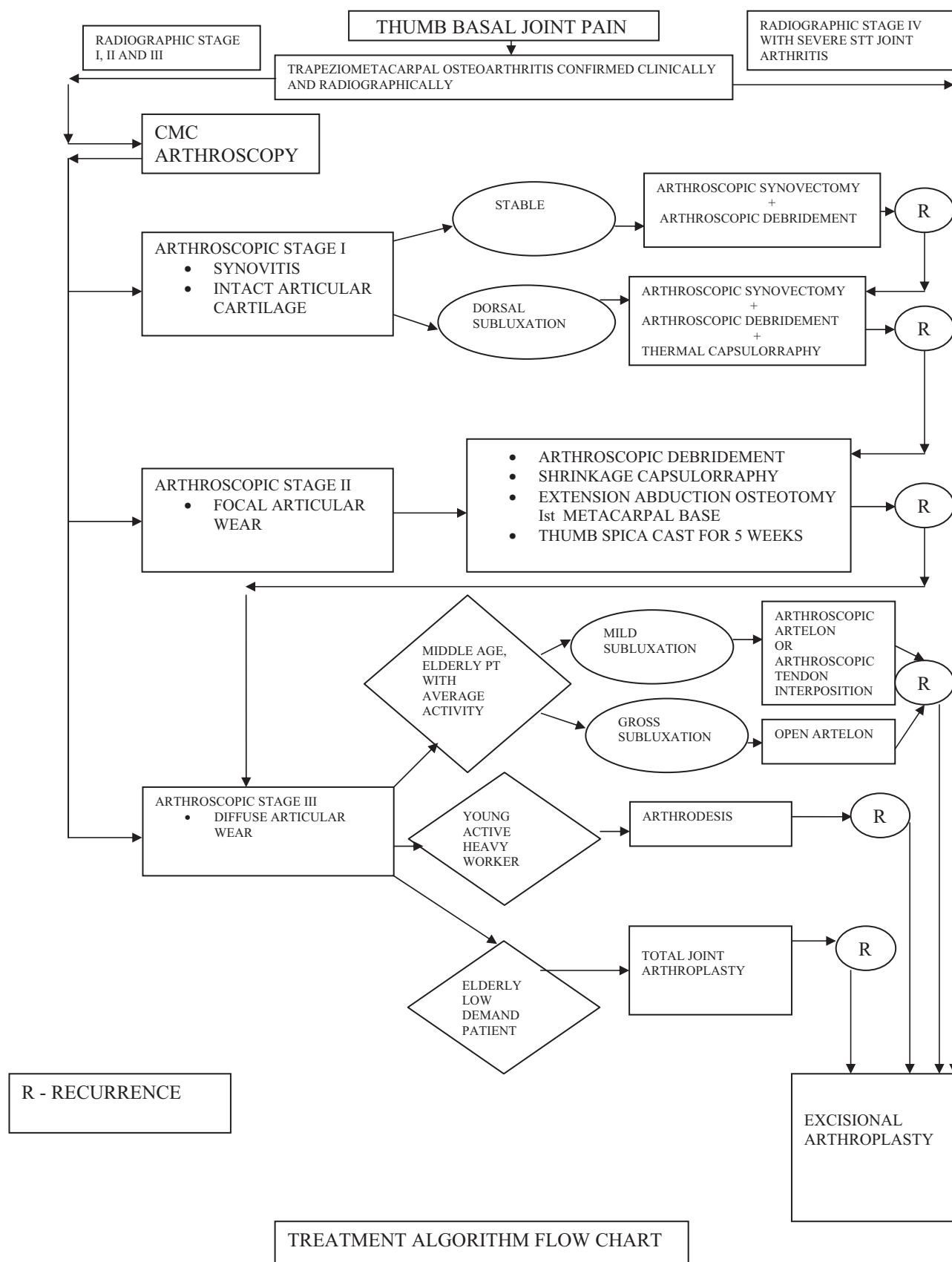


Figure 6. Treatment algorithm for thumb Basal joint arthritis.

treatment needs to be further assessed by evaluating long-term clinical results.

According to the arthroscopic classification proposed, I recommend arthroscopic synovectomy and debridement of the basal joint in patients with stage 1 arthritis. In patients with stage 2 disease, synovectomy and debridement is combined with dorsoradial osteotomy of the 1st metacarpal. In both of these stages, thermal shrinkage is used to manage ligamentous laxity. Finally, for stage 3 of the disease, arthroscopic interposition arthroplasty is my treatment of choice, although other factors must be considered in making this determination.

Arthroscopic assessment of the trapeziometacarpal joint allows direct visualization of all components of the joint including synovium, articular surfaces, ligaments, and the joint capsule. It also allows for the extent of joint pathology to be evaluated and staged with intraoperative management decision-making based on this information. I recommend this arthroscopic staging to ensure better judgment of this condition to provide the most adequate treatment option to patients who have this disabling condition.

Future studies assessing the clinical long-term results utilizing arthroscopy will likely ensure its place in the treatment armamentarium for trapeziometacarpal osteoarthritis.

Metacarpophalangeal Arthroscopy

Despite the fact that arthroscopy of the metacarpophalangeal joints of the hand was first described nearly 30 years ago, the clinical utility and indications remain obscure. In fact, most orthopedic surgeons are completely unaware of the possibility of using the ubiquitous arthroscope to explore this joint, which can be afflicted with diverse pathology. Furthermore, hand surgeons rarely use this technology despite being faced daily with challenging clinical problems within this small but critical joint. One can speculate as to reasons why this is the case, but I suspect that minimal reporting in the literature as well as the lack of direct teaching of this technique has contributed to the poor utilization of what is potentially a very useful addition to our treatment armamentarium.

Dr. YC. Chen first described arthroscopy of the MCP joints, among other small joints of the hand, in his landmark article in *Orthopedic Clinics of North America* in 1979.¹ Despite a very simplistic review, this article first described use of the Watanabe no. 24 arthroscope within the wrist, metacarpophalangeal joints, and even interphalangeal joints of the hand.

Although he described both proximal interphalangeal (PIP) and distal interphalangeal (DIP) joints being scoped, there was strangely no mention of the trapeziometacarpal joint. Nevertheless, he first introduced the concept of placing a small arthroscope into the metacarpophalangeal joint of several digits including the thumb. He was the first to describe the anatomy, albeit cursory, and he also presented several case reports where he described the arthroscopic findings and clinical relevance. In total, he described 90 arthroscopies carried out in multiple joints encompassing 34 clinical cases as well as using 2 cadaver arms in the period November 1973 to August 1978. Surprisingly, this novel concept was not expanded upon until much later.

Vaupel and Andrews, a well-known arthroscopic surgeon, described the first case report involving arthroscopic treatment of the metacarpophalangeal joint 6 years after Chen's report.³⁹ In this particular case, they described a professional golfer who was impaired due to a 1-year history of chronic painful synovitis within the thumb metacarpophalangeal joint. They performed a synovectomy as well as arthroscopic burring of a small chondral defect that had been identified. The patient did extremely well and was able to return to his sport within a 6-month period and was essentially pain free at his nearly 2-year follow-up examination. This was published in the *American Journal of Sports Medicine* where hand surgeons were unlikely to be exposed to this article. Despite an excellent clinical outcome and a logical approach to care, neither general indications for utilizing this small arthroscopic technique were outlined, nor were further clinical recommendations made. It was not until 2 years later, in 1987, when Wilkes presented the first series of a pathology treated with arthroscopic means in the metacarpophalangeal joint.⁴⁰ This consisted of arthroscopic rheumatoid synovectomy on 13 joints within 5 patients, all having a chronic rheumatoid arthritis. These patients lacked the usual joint subluxation or destruction but did have notable synovitis that was found within the recesses of the collateral ligament origins. There was an adequate follow-up of 4 years, which did demonstrate that there was recurrence of pain and that the technique did not seem to alter the natural history of this disease at the MCP joint. Unfortunately, this critical series was published within the *Journal of the Medical Association of Georgia* and, hence, did not have broad exposure to either hand surgeons or arthroscopic surgeons within the field of general orthopedics or sports medicine. For these

reasons, the subsequent paper in the literature utilizing this technique was not seen until 1994 where it finally reached the *Journal of Hand Surgery - British Volume* where a case report was presented.⁴¹ The patient was a young male presenting with swelling and recurrent locking of the metacarpophalangeal joints of both the index and middle fingers bilaterally. This is a typical presentation for hemochromatosis. Up until that time, the treatment of arthropathy was osteotomy and arthroplasty or even a joint arthrodesis for more advanced cases. This is a rarely seen hematologic condition that is actually treated with phlebotomy, and the joint manifestations are poorly understood. However, at that time, it was clear to these surgeons that arthroscopy presented an excellent alternative to open surgery with better visualization of the joint with subsequent treatment of the synovitis and a more rapid recovery due to its minimally invasive nature. The emphasis of the case report was on the condition itself and did not give any further recommendations other than stating that this case suggested that arthroscopic surgery is "of value." Likely due to the fact that the arthroscopic treatment was overshadowed by the unusual pathology being treated, the common clinical application of this technology was still not heralded.

It was not until 1995 when Ryu and Fagan presented their series on the treatment of the ulnar collateral ligament Stener lesion that we could see a common clinical application for this new technology.⁴² Their series described an arthroscopic reduction of a Stener lesion on 8 thumbs with an average follow-up period of just over 3 years. The technique simply involved reduction of the Stener lesion into the joint so that the avulsed ligament would now be juxtaposed to its insertion site on the base of the proximal phalanx. Previously, the ligament had been sitting outside the adductor aponeurosis and could not heal in appropriate position. Once the reduction was performed, the ligament ends were debrided and the joint pinned for stability. Upon removing the cast, a brief course of therapy was introduced, and at follow-up no patient reported any pain or functional limitation. There was an excellent range of motion with strength parameters equal to or often greater than the thumb on the unaffected side. The only complication was a single pin tract infection. Their results indicated that an arthroscopic reduction of a Stener lesion obviated the need for open repair and all of its consequent complications such as prolonged recovery and stiffness. This clinical series represented the first clinical application to a common

problem that would then serve as a frequent reason to perhaps utilize arthroscopic treatment of pathology in this joint. There was, however, no mention of bony gamekeeper's lesions, nor was there a comparative analysis with the open technique. Perhaps the greatest contribution of this paper was that it was presented in a widely read journal. This most likely introduced the concept of arthroscopic surgery in this small joint for the first time to the majority of the hand surgery community. Nevertheless, despite the fact that this paper was published more than 10 years ago, the technique remains minimally utilized and there have been few clinical series since then.

In 1999, Rozmaryn and Wei presented the first generalized paper on the technical aspects of metacarpophalangeal arthroscopy with further discussion on the possible indications and advantages of this little-used technique.⁴³ They speculated that there may be a perception that the MCP joint is simply too small to perform arthroscopic procedures in any practical or relevant manner. While not discussing follow-up of a variety of indications, they did make the first mention of the broad indications that might be treated with this procedure. They specifically mentioned joint synovectomies and biopsies as previously mentioned and reiterated the possibility of collateral ligament debridement, while adding the concept of ligament repair as a possibility. They also mentioned removal of loose bodies, treatment of osteochondral lesions, management of juxta-articular lesions, and treatment of intra-articular fractures and other possible clinical applications. They too noted that only a handful of case reports were present in the literature, and they explained why this technique was not expanded upon. It should be noted that this was published in the journal *Arthroscopy: The Journal of Arthroscopic-Related Surgery* in 1999, and this too would have led to little exposure to dedicated hand surgeons. Their report not only discussed some technical aspects but also described the anatomic landmarks for the first time since Dr. Chen's simplistic description with a much poorer arthroscope 20 years prior. They made a general observation that the advantages of arthroscopic as opposed to open techniques was similar to those experienced in larger joints and that perhaps with time, many more indications would clearly emerge.

The same year of Rozmaryn and Wei's technical article, a broad review article was published by Slade and Gutow⁴⁴ in *Hand Clinics* and titled "Arthroscopy of the Metacarpophalangeal Joint." For the first time, a broad analysis of the technique was presented,

including detailed technical explanations, a description of the broad clinical applications, as well as some illustrative cases. They also mentioned the rare complications and how to avoid them. Interestingly, the concept of a triumph of technology over reason was also mentioned, lending credence to the theory that arthroscopy of this small joint may not have gained widespread acceptance due to the fact that it may just not be practical. They emphasized that small joint arthroscopy in these joints requires not only specialized instrumentation but also a thorough knowledge of the anatomy within these joints. Their broad review soon revealed that there were a wide variety of indications that could greatly benefit from this technology. Detailed treatment techniques were described with several case examples, particularly in the area of intra-articular fracture treatment. A novel technique was also described where arthroscopy could be combined with small bone anchor application for reattachment of collateral ligament injuries. This obviously demonstrates a challenging technical exercise, but the authors were quick to point out the relative advantages of this method. In their discussion with German colleagues, who had begun comparing arthroscopic synovectomies in rheumatoid patients with other joints treated in the same patient with open means, both surgeons and the patients were impressed with the diminished postoperative swelling and the improvement in rehabilitation with earlier return to activity. This particular series has not been published but represents a possible advantage of the arthroscopic technique as opposed to open means. In fact, in that same year, there was an obscure article in the rheumatology literature that discussed use of "mini-arthroscopy" of metacarpophalangeal joints in staging a synovitis and using this as an effective biopsy tool. The article was written by rheumatologists in Germany and emphasized the scoring system of synovitis within rheumatoid patients with little discussion of the operative technique.⁴⁵ They simply used this as a tool for assessing the degree of disease involvement but again emphasized its clinical utility. The authors believed that microarthroscopy provided an objective technique for joint evaluation and microscopic assessment and allowed visual-guided synovial biopsy with increased accuracy and decreased the risk of any sampling errors. They performed this under local anesthesia, indicating that general anesthesia was not necessary, and it could be easily done within an outpatient framework. Obviously, if the rheumatologists could see the great benefit of this technique,

hand as well as arthroscopic surgeons could certainly expand upon its clinical utility. In the same year, Wei, who had co-written the first technical description of metacarpophalangeal joint arthroscopy, presented a series of arthroscopy synovectomy within refractory rheumatoid arthritis.⁴⁶ He described a series of 21 patients treated with synovectomy with good short-term results. Although the article was predominately meant to be a technique article, he believed the short-term results were promising and that the utility of this procedure in other types of arthritis or other orthopedic conditions was warranted. He raised the question of what is the long-term effect of this procedure on joint preservation as well as what is the optimal timing for this surgery in the rheumatoid patients. Although we certainly do not have the answers to these questions, it is hoped that increased utilization of metacarpophalangeal joint arthroscopy may answer this and many other questions.

Sekiya and colleagues expanded on previous surgeons' descriptions by evaluating 21 patients with rheumatoid arthritis in 27 proximal interphalangeal joints and 16 metacarpophalangeal joints. This was apparently the first clinical description of PIP joint arthroscopy and also added further information regarding metacarpophalangeal joint arthroscopic surgery.⁴⁷ They, too, found that arthroscopic assessment of the articular surface and synovial membrane was an excellent application of this tool and that more accurate biopsies could be taken. They speculated that arthroscopy for the small joints in the hands "will become a standard procedure in the near future." However, their study did not assess other pathologies. Gaspar et al described a technique of synovial biopsy of metacarpophalangeal joint using a needle arthroscope, which can be of good use in rheumatoid patients.⁴⁸ It is apparent that there is a paucity of clinical articles in the literature and that further discussion regarding the indications and clinical application of this technique is necessary to stimulate the hand surgeon to include this tool in his spectrum of treatment options. Whereas the arthroscopic surgeon, commonly identified as a sports medicine specialist, may utilize this technique, it will likely remain for the hand surgeon to expand its clinical applications. This is simply because the variety of pathology seen in the metacarpophalangeal joints is most commonly assessed by hand surgeons, and it is up to this group of surgeons to expand the applications of this still underutilized technique.

Pathology of the metacarpophalangeal joint is rel-

atively common. Acute trauma can involve any one of these joints with the thumb being by far the most commonly afflicted. The so-called gamekeeper's thumb is a frequent injury seen in any hand surgeon's practice. My experience with the arthroscopic reduction and internal fixation of the bony gamekeeper's thumb has been encouraging.⁴⁹ Bony gamekeeper's thumb, which is a relatively common injury, provides more treatment options compared with the classic Stener lesion, which traditionally requires open repair of the avulsed ligament. Hence the technique of arthroscopic fixation of this avulsion fracture can be used effectively in routine practice. Acute trauma can also involve the finger MCPs with both ligamentous injuries and articular fractures being occasionally seen. So-called overuse syndromes may reflect a previously unrecognized acute injury that was not addressed or may simply be a more chronic synovitis. Arthroscopy of these small joints will not only assist in diagnosing the condition, but also, as will be illustrated, can serve to provide treatment.

Technique

An arthroscope 1.9 mm in diameter will be necessary to explore these small joints. Generally, the 30° scope commonly used by maxillofacial surgeons for temporomandibular pathology is used. Newer arthroscopes as small as 1 mm are now available and will make this technique even easier. A 2.0-mm shaver is usually the main operative instrument although small radiofrequency probes, both for ablation and shrinkage, are frequently used.

In these smaller joints, it is much easier to proceed with local anesthesia and sedation. Several milliliters of lidocaine are introduced into the joint once the hand is suspended using a single Chinese fingertrap on the affected digit. Adequate sedation is then achieved to allow elevation of the tourniquet for the necessary time period.

It is particularly important to introduce the trocar into the joint in atraumatic fashion. These joint spaces are minimal, and it is feasible to cause considerable iatrogenic injury if care is not taken. The interval between metacarpal head and proximal phalanx base is quite narrow, and it is recommended to find the appropriate level and insertion angle by inserting a small curved clamp once the joint is sufficiently distended with lidocaine or saline solution. The arthroscope is then introduced at this same angle, and a thorough joint inspection is performed (Fig. 7). The portals are quite simple as they lie on either side of the visible extensor

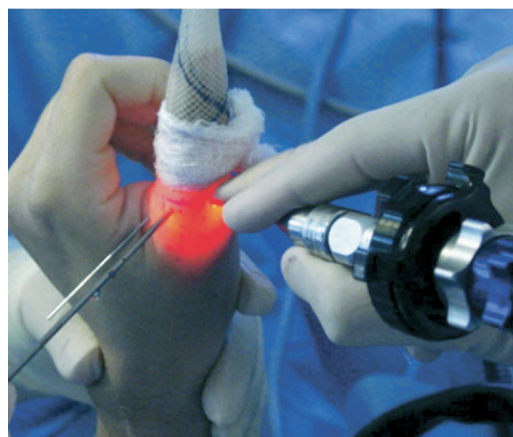

Figure 7. Photograph showing arthroscopy of the thumb MCP joint with K-wire holding the reduction.

tendon. Occasionally, a third portal might be used for outflow and is placed by palpating the capsule, identifying the interval as seen on the monitor, and then passing an 18-gauge needle. A synovectomy must always be initially performed as only this will allow thorough inspection of the joint. As this is done with a small full-radius shaver, the capsule and ligamentous structures become more apparent. A radiofrequency ablator probe can make this process more efficient and less tedious. It is important to use this sparingly, as the joint capsule is relatively thin and subcutaneous, and thermal injury can occur. Once synovectomy is performed, the surgeon can now sequentially identify any abnormalities. This should be done in a routine systematic fashion to avoid missing any pathology. My preference is to begin on one collateral ligament, then assess the volar plate, then the contralateral ligament followed by the dorsal capsule and extensor mechanism. The articular surface of both proximal phalanx and metacarpal head is then assessed. Once the particular pathology is identified and appropriately addressed, the arthroscope is removed and portals are closed with benzoin and steri-strips only. The thumb MCP is protected with a short arm thumb spica splint in extension. Arthroscopy of any of the fingers will require a dorsal metacarpophalangeal block splint in flexion to allow the collateral ligaments to heal in their most taut position so that there is no resultant loss in motion. Time of immobilization is determined by the type and extent of pathology found during the arthroscopic intervention. Therapy after operation may play a role but is rarely needed for a prolonged course.

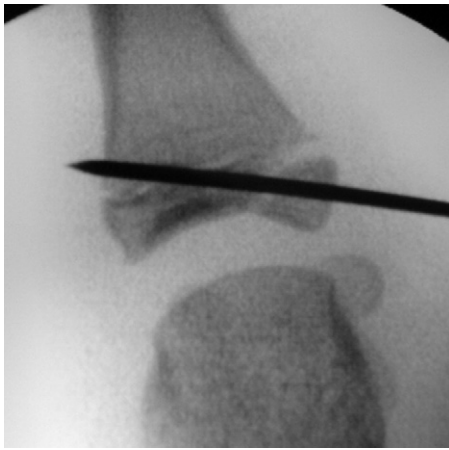


Figure 8. Intraoperative fluoroscopic view showing reduced bony gamekeeper's avulsion fracture of thumb MCP in a young adolescent patient.

Indications of Metacarpophalangeal Arthroscopy

Surgical indications to perform MCP arthroscopy will usually involve chronic complaints as opposed to acute injury. Most acute trauma about these joints can be managed conservatively with a trial of immobilization. The thumb ulnar collateral ligament avulsion is a notable exception where open repair of a Stener lesion is usually performed. Even here, however, an arthroscopic repair has been described in the literature.³⁹ As the surgeon becomes more adept at this small joint arthroscopy, the more acute indications may evolve as one can make a more accurate assessment of the extent of injury and often provide more precise treatment for this articular pathology.

Acute indications generally involve an associated

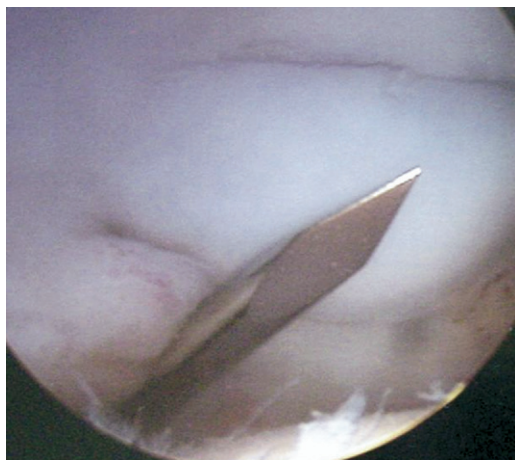


Figure 9. Arthroscopic view showing the arthroscopic reduction of the avulsed fragment with the K-wire, demonstrating the necessary angle for fragment fixation.

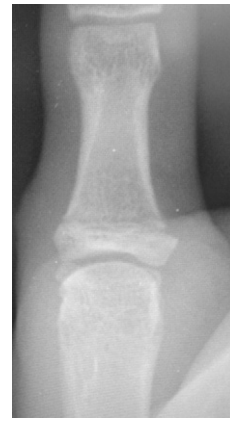

Figure 10. Radiograph of the same patient of Figure 9 showing consolidation of the fracture at 9 weeks after surgery, 1 month after pin removal.

fracture that will need articular reduction. This is because the vast majority of ligamentous injuries will heal with conservative treatment or are so severe that they will be treated open to correct the instability. Perhaps, the best acute indication is reduction of an avulsion fracture with a rotated fragment from the collateral ligament insertion (Fig. 8).⁴⁹ A hook probe is used to derotate the bony fragment with arthroscopic visualization. K-wire fixation can then be added with fluoroscopic confirmation. (Figs. 8, 9) A less common lesion would be a die-punch articular fracture, usually of the proximal phalanx base, where the scope can be used to achieve the best articular reduction possible. At that time, a synovectomy as well as removal of floating loose osteochondral fragments can be performed. This has an added benefit of reducing the inflammatory process besides reducing the fracture. This arthroscopic technique has the obvious advantage of a more precise articular reduction (Figs. 8, 9) with the added benefit of minimal cap-

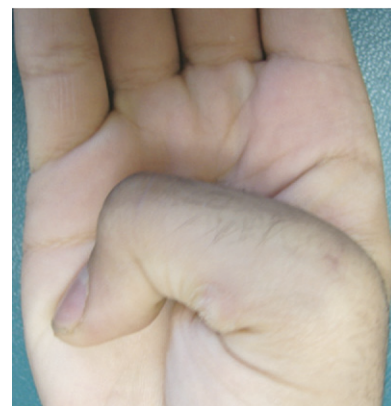

Figure 11. Range of motion at the 1st MCP joint in the same patient of Figures 9 and 10 at 9 weeks follow-up.

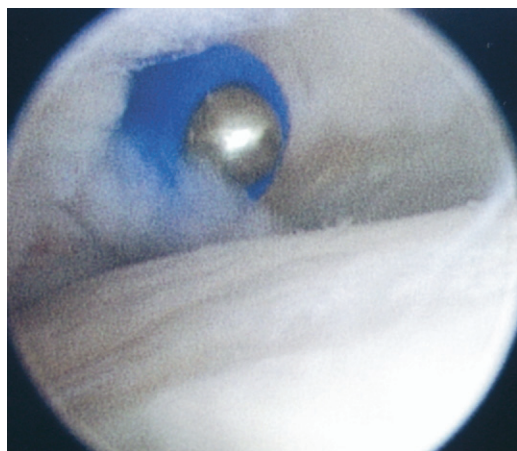


Figure 12. Arthroscopic view showing radiofrequency thermal capsulorraphy procedure after synovectomy in a patient with synovitis and articular changes in the 2nd MCP joint.

sular scarring and consequently faster recovery of a full range of motion (Figs. 10, 11).⁴⁹ As in any other arthroscopy, assessment of associated lesions such as ligament or capsular injury can also be assessed and treated.

Chronic processes affecting the MCP joint tend to be the most common indications. This is perhaps because there are few options in a persistently painful knuckle joint. Acute injuries often improve with appropriate rehabilitation and/or immobilization while more severe trauma is managed with open repairs. Therefore, persistent pain despite ample conservative treatment in both thumb and finger MCP injury is the most common indication for MCP arthroscopy. It is not uncommon to encounter persistent symptoms after cast treatment for a skier's thumb. This can be due to a more severe ligamentous injury than originally

surmised or a concomitant articular cartilage injury with accompanying persistent synovitis. Sometimes the contralateral ligament is injured as well and was not completely addressed. An arthroscopic evaluation determines the location and extent of injury and gives an opportunity to provide treatment, whether by simple debridement and/or thermal capsulorraphy. This type of complaint is often managed by a course of nonsteroidal anti-inflammatory drugs or a series of cortisone injections. These treatments may only provide temporary relief, if any, and cannot be continued indefinitely. This is where the great value of arthroscopy lies as it provides a viable option to make both a definitive diagnosis and institute a treatment based on these findings.

Occult pain often associated with chronic swelling may be an indication to proceed with arthroscopic evaluation as well. This may have been from an unrecognized injury, early presentation of osteoarthritis, or an idiopathic synovitis. Steroid injections are often efficacious here but can lead to acceleration of cartilage and capsular degeneration. Arthroscopic debridement (Fig. 12) will avoid this complication while perhaps retarding the degenerative process. A further benefit is that complications are negligible and the recovery is rapid (Fig. 13).

The earliest stages of osteoarthritis may not be seen on plain radiographs, and the diagnosis is often a clinical one. After adequate conservative treatment with nonsteroidal anti-inflammatory drugs and perhaps a course of therapy, the logical next level of treatment remains an intra-articular corticosteroid injection. If symptoms recur despite several injections, arthroscopic debridement becomes the best option

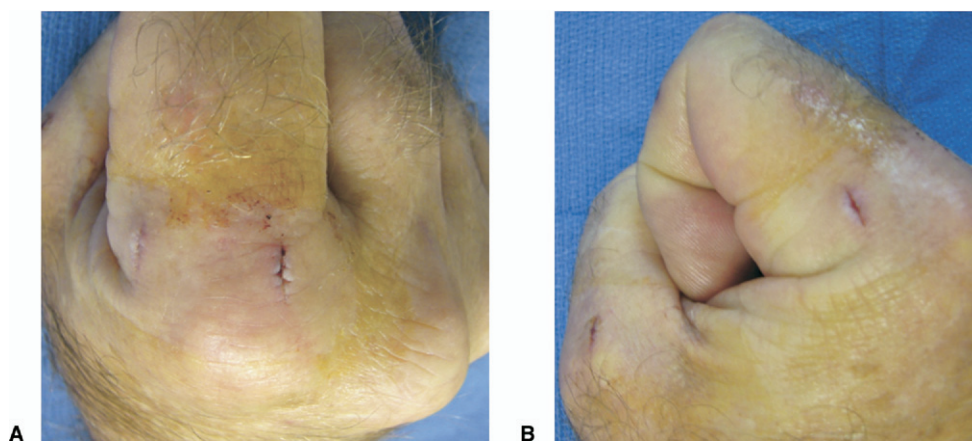


Figure 13. (a) Frontal and (b) lateral photographs showing rapid recovery of function in the same patient of Figure 12 at 4 days after arthroscopic synovectomy and debridement of both index and thumb MCP joints. Patient noted immediate resolution of night pain in these chronically swollen joints.

short of joint replacement. Open synovectomies are difficult because of poor visualization and limited access to all regions of the joint and can lead to considerable stiffness after operation. Although silicone arthroplasty remains the gold standard treatment for advanced rheumatoid involvement of the MCP joints, post-traumatic arthrosis and osteoarthritis are not good indications for replacement arthroplasty. Arthroscopy provides a good treatment alternative before resorting to the newer nonconstrained replacement options now available.

Inflammatory arthritis, such as rheumatoid, is generally managed with systemic pharmacotherapy and in late stages with replacement arthroplasty. Occasionally, a mono- or pauci-articular form is encountered, and an arthroscopic biopsy may assist in making the diagnosis. Early involvement of these joints may warrant an arthroscopic synovectomy and capsular shrinkage. This is best suited for the 1–2 joints most involved, where one can hope to retard the destructive process. Long-term results of this procedure remain to be demonstrated.

Summary

Arthroscopy has become a vital part of an orthopedic surgeon's armamentarium in treating large joint pathology. Advances in technology have now allowed us to apply this benefit to the smallest joints, such as the metacarpophalangeal and trapeziometacarpal joints. Osteoarthritis will likely remain the most common indication for basal joint arthroscopy while chronic pain and inflammation are useful indications for metacarpophalangeal arthroscopy. As in any new technique, the appropriate and most suitable indications will evolve over time. Further clinical studies are necessary to validate the technique and to encourage further implementation as well as improvements in the instrumentation.

Received for publication December 29, 2006; accepted February 18, 2007.

No benefits in any form have been received or will be received from a commercial party related directly or indirectly to the subject of this article.

Corresponding author: Alejandro Badia, MD, FACS, Miami Hand Center, 8905 SW 87th Ave., Miami, FL 33176; e-mail: alex@surgical.net

Copyright © 2007 by the American Society for Surgery of the Hand
0363-5023/07/32A05-0019\$32.00/0
doi:10.1016/j.jhsa.2007.02.020

References

- Chen YC. Arthroscopy of the wrist and finger joints. *Ortho Clin North Am* 1979;10:723–733.
- Menon J. Arthroscopic management of trapeziometacarpal joint arthritis of the thumb. *J Arthr Rel Surg* 1996;12:581–587.
- Berger RA. A technique for arthroscopic evaluation of the first carpometacarpal joint. *J Hand Surg* 1997;22A:1077–1080.
- Menon J. Arthroscopic evaluation of the first carpometacarpal joint. [Letter to the Editor] *J Hand Surg* 1998;23A:757.
- Berger RA. Arthroscopic evaluation of the first carpometacarpal joint. [Reply] *J Hand Surg* 1998;23A:757.
- Osterman AL, Culp R, Bednar J. Arthroscopy of the thumb carpometacarpal joint. *Arthroscopy* 1997;13:3.
- Weitbrecht J. *Syndesmology*. Philadelphia: WB Saunders, 1969 [originally published 1742].
- Bettinger PC, Linscheid RL, Berger RA, Cooney WP, An Kai-Nan. An anatomic study of the stabilizing ligaments of the trapezium and trapeziometacarpal joint. *J Hand Surg* 1999;24A:786–798.
- Van Brenk B, Richards RR, Mackay MB, Boynton EL. A biomechanical assessment of ligaments preventing dorsoradial subluxation of the trapeziometacarpal joint. *J Hand Surg* 1998;23A:607–611.
- Zancolli EA, Cozzi EP. The trapeziometacarpal joint: anatomy and mechanics. In: Zancolli E, Cozzi EP, eds. *Atlas of surgical anatomy of the hand*. New York: Churchill Livingstone, 1992:443–444.
- Xu L, Strauch RJ, Ateshian GA, et al. Topography of the osteoarthritic thumb carpometacarpal joint and its variation with regard to gender, age, site, and osteoarthritic stage. *J Hand Surg* 1998;23A:454–464.
- Pellegrini VD. Pathomechanics of the thumb trapeziometacarpal joint. *Hand Clin (Thumb Arthritis)* 2001;17:175–184.
- Bettinger PC, Berger RA. Functional ligamentous anatomy of the trapezium and trapeziometacarpal joint (gross and arthroscopic). *Hand Clin (Thumb Arthritis)* 2001;17:151–168.
- Orellana MA, Chow JC. Arthroscopic visualization of the thumb carpometacarpal joint: introduction and evaluation of a new radial portal. *Arthroscopy* 2003;19:583–591.
- Walsh EF, Akelman E, Fleming BC, DaSilva MF. Thumb carpometacarpal arthroscopy: a topographic, anatomic study of the thenar portal. *J Hand Surg* 2005;30A:373–379.
- Gonzalez MH, Kemmler J, Weinzwieg N, Rinella A. Portals for arthroscopy of the trapeziometacarpal joint. *J Hand Surg* 1997;22B:574–575.
- Culp RW, Rekant MS. The role of arthroscopy in evaluating and treating trapeziometacarpal disease. *Hand Clin (Thumb Arthritis)* 2001;17:315–319.
- Badia A. Trapeziometacarpal arthroscopy: a classification and treatment algorithm. *Hand Clin* 2006;22:153–163.
- Eaton RG, Glickel SZ. Trapeziometacarpal osteoarthritis. Staging as a rationale for treatment. *Hand Clin* 1987;3:455–471.
- Fulton DB, Stern PJ. Trapeziometacarpal arthrodesis in primary osteoarthritis: a minimum two year follow-up study. *J Hand Surg* 2001;26A:109–114.
- Lopez MJ, Hayashi K, Fanton GS, Thabit G, Markel MD. The effects of radiofrequency energy on the ultrastructure of joint capsular collagen. *Arthroscopy* 1998;14:495–501.
- Hecht P, Hayashi K, Cooley AJ, Lu Y, Fanton GS, Thabit G, Markel MD. The thermal effect of monopolar radiofre-

- quency energy on the properties of joint capsule. *Am J Sports Med* 1998;26:808–814.
23. Wilson J. Basal osteotomy of the first metacarpal in the treatment of arthritis of the carpometacarpal joint of the thumb. *Br J Surg* 1973;60:854–858.
24. Tomaino MM. Treatment of Eaton stage I trapeziometacarpal disease. Ligament reconstruction or thumb metacarpal extension osteotomy? *Hand Clin* 2001;17:197–205.
25. Minami A, Iwasaki N, Kutsumi K, Suenaga N, Yasuda K. A long-term follow-up of silicon-rubber interposition arthroplasty for osteoarthritis of the thumb carpometacarpal joint. *Hand Surg* 2005;10:77–82.
26. Nilsson A, Liljensten E, Begstrom C, Sollerman C. Results from a degradable TMC joint spacer (Artelon) compared with tendon arthroplasty. *J Hand Surg* 2005;30A:380–389.
27. Eaton RG, Glickel SZ, Littler JW. Tendon interposition arthroplasty for degenerative arthritis of the trapeziometacarpal joint of the thumb. *J Hand Surg* 1985;10A:645–654.
28. Burton RI, Pellegrini VD Jr. Surgical management of basal joint arthritis of the thumb: part II. Ligament reconstruction with tendon interposition arthroplasty. *J Hand Surg* 1986;11A:324–332.
29. Tomaino MM, Pellegrini VD Jr, Burton RI. Arthroplasty of the basal joint of the thumb: long-term follow-up after ligament reconstruction with tendon interposition. *J Bone Joint Surg* 1995;77A:346–355.
30. Lins RE, Gelberman RH, McKeon L, Katz JN, Kadiyala RK. Basal joint arthritis: trapeziectomy with ligament reconstruction and tendon interposition arthroplasty. *J Hand Surg* 1996;21A:202–209.
31. Braun RM. Total joint replacement at the base of the thumb—preliminary report. *J Hand Surg* 1982;7A:245–251.
32. Badia A, Sambandam SN. Total joint arthroplasty in the treatment of advanced stages of thumb carpometacarpal joint osteoarthritis. *J Hand Surg* 2006;31A:1605–1614.
33. Kriegs Gabriele-Au, et al. Ligament reconstruction with or without tendon interposition to treat primary thumb carpometacarpal osteoarthritis: a prospective randomized study. *J Bone Joint Surg* 2004;86A:209–218.
34. Froimson AI. Tendon arthroplasty of the trapeziometacarpal joint. *Clin Orthop* 1970;70:191–199.
35. Swigart CR, Eaton RG, Glickel SZ. Splinting in the treatment of arthritis of the first carpometacarpal joint. *J Hand Surg* 1999;24A:86–91.
36. Bettinger PC, Linscheid RL, Cooney WP III, An KN. Trapezial tilt: a radiographic correlation with advanced trapeziometacarpal joint arthritis. *J Hand Surg* 2001;26A:692–697.
37. Barron OA, Eaton RG. Save the trapezium: double interposition arthroplasty for the treatment of stage IV disease of the basal joint. *J Hand Surg* 1998;23A:196–204.
38. Badia A, Young L, Riano F. Bilateral arthroscopic tendon interposition arthroplasty of the thumb carpometacarpal joint in a patient with Ehlers-Danlos syndrome: A case report. *J Hand Surg* 2005;30A:673–676.
39. Vaupel GL, Andrews JR. Diagnostic and operative arthroscopy of the thumb metacarpophalangeal joint. a case report. *Am J Sports* 1985;13:139–141.
40. Wilkes LL. Arthroscopic synovectomy in the rheumatoid metacarpophalangeal joint. *J Med Assoc Georgia* 1987;76:638–639.
41. Leclercq G, Schmitgen G, Verstreken J. Arthroscopic treatment of metacarpophalangeal arthropathy in haemochromatosis. *J Hand Surg* 1994;19B:212–214.
42. Ryu J, Fagan R. Arthroscopic treatment of acute complete thumb metacarpophalangeal ulnar collateral ligament tears. *J Hand Surg* 1995;20A:1037–1042.
43. Rozmaryn LM, Wei N. Metacarpophalangeal arthroscopy. *Arthroscopy* 1999;15:333–337.
44. Slade JF III, Gutow AP. Arthroscopy of the metacarpophalangeal joint. *Hand Clin* 1999;15:501–527.
45. Ostendorf B, Scherer A, Wirrwar A, Hoppin JW, Lackas C, Schramm NU, et al. Miniarthroscopy of metacarpophalangeal joints in rheumatoid arthritis. Rating of diagnostic value in synovitis staging and efficiency of synovial biopsy. *J Rheumatol* 1999;26:1901–1908.
46. Wei N, Delauter SK, Erlichman MS, Rozmaryn LM, Beard SJ, Henry DL. Arthroscopic synovectomy of the metacarpophalangeal joint in refractory rheumatoid arthritis: a technique. *Arthroscopy* 1999;15:265–268.
47. Sekiya I, Kobayashi M, Taneda Y, Matsui N. Arthroscopy of the proximal interphalangeal and metacarpophalangeal joints in rheumatoid hands. *Arthroscopy* 2002;18:292–297.
48. Gaspar L, Szekanecz Z, Dezso B, Szeged G, Gsernatony Z, Szepesi K. Technique of synovial biopsy of metacarpophalangeal joints using the needle arthroscope. *Knee Surg Sports Traumatol Arthrosc* 2003;11:50–52.
49. Badia A. Arthroscopic reduction and internal fixation of bony gamekeepers thumb. *Orthopedics* 2006;29:675–678.